

## Streamlining diagnosis with urinary sediment microscopy: a case of deteriorating renal function in a kidney transplant patient

Nuno Moreira Fonseca<sup>1</sup>, David Navarro<sup>1</sup>, Mário Góis<sup>1,2</sup>, Helena Sousa<sup>1,2</sup>, Inês Aires<sup>1</sup>, Fernando Nolasco<sup>1</sup>

<sup>1</sup> Nephrology Department, Hospital de Curry Cabral, Centro Hospitalar Universitário de Lisboa Central

<sup>2</sup> Laboratory of Renal Morphology, Nephrology Department, Hospital Curry Cabral – Centro Hospitalar Universitário de Lisboa Central

Received for publication: Dec 10, 2018

Accepted in revised form: Dec 13, 2018

### CLINICAL PRESENTATION

We present the case of a 71-year-old caucasian male with chronic kidney disease secondary to Anti-Neutrophilic Cytoplasmic Autoantibody (ANCA) vasculitis. Past medical history included hypertension, previous smoking (stopped 10 years before), and biliary lithiasis. The patient underwent expanded criteria deceased donor kidney transplantation at our unit in late 2016, with 6 HLA-mismatches and cold ischemia time of 7 hours. Both the donor and recipient tested positive for IgG anti-cytomegalovirus. Induction immunosuppression used was a 7-day cycle of intravenous thymoglobulin. The immediate postoperative period was uneventful and the patient was discharged after 14 days with a serum creatinine of 1.3 mg/dL. Maintenance immunosuppression included tacrolimus, mycophenolate mofetil, and prednisolone, as per our unit protocol.

The first year after transplantation was uneventful except for a positive viremia for Polyomavirus (PV) present at discharge (99,220 copies/mL). Immunosuppression was progressively reduced throughout the first year, with renal function remaining stable (Table 1). Despite progressive reduction of immunosuppression, PV viral loads remained positive at 14 months after transplantation. At the 8th month after transplantation, the patient presented positive Cytomegalovirus (CMV) viremia (167 UI/mL). Valganciclovir was increased to 450 mg bid with normalization of viremia the following month.

At 14 months post-transplant, renal function worsened (serum creatinine of 1.6 mg/dL). At this time, levels of tacrolimus were within intended target; donor specific antibodies were negative, and there were no

**Table 1**

Patient evolution and treatment management during follow-up

	Discharge	Month 1	Month 3	Month 5	Month 8	Month 10	Month 11	Month 14
Serum creatinine mg/dL	1.3	1.1	1.2	1.1	1.2	1.4	1.3	1.6
PV copies/mL	99220	66740	4950	18420	4400	22070	17614	70600
CMV UI/mL		Negative	Negative	Negative	167	Negative	Negative	Negative
ANCA MPO/PR3	Negative	Negative						Negative
DSA	Negative						Negative	Negative
Tacrolema ng/mL	6.9	6.8	9.2	8.6	7.4	8.3	8.6	7
Tacrolimus LP mg/day	9	9	7.5	6.5	5.5	4.5	4	3.5
MMF mg/day	750x2	250x2	250	250	250x2	250x3	250x3	250x2
Prednisolone mg/day	20	15	12.5	7.5	10	5	5	2.5
Lenulfamide mg/day			10	20	20	20	20	20
Ganciclovir mg/day	450	450	450	450	900	450	450	450

apparent hemodynamic changes. The patient was hospitalized for further investigation. On admission the patient’s urinalysis was as shown in Table 2. We performed contrast-phase microscopy analysis of urine sediment. Findings are shown in Figures 1 and 2.

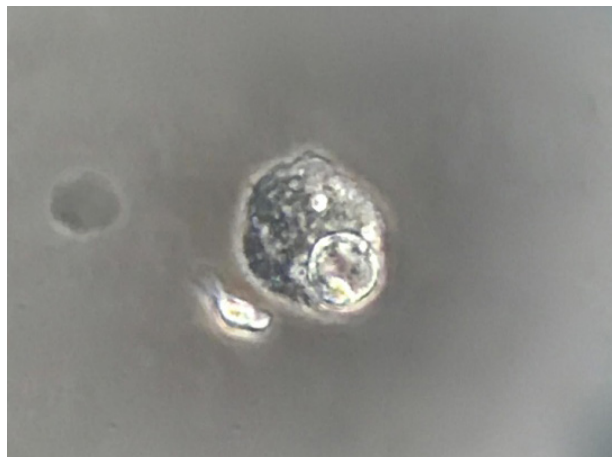
**Table 2**

Urinalysis

<b>Specific gravity</b>	1.010	<b>Albumin</b>	vestigial
<b>pH</b>	5	<b>Hemoglobin</b>	negative
<b>Glucose:</b>	negative	<b>Leukocyte esterase</b>	negative
<b>Nitrites:</b>	negative	<b>Uobilinogen</b>	negative

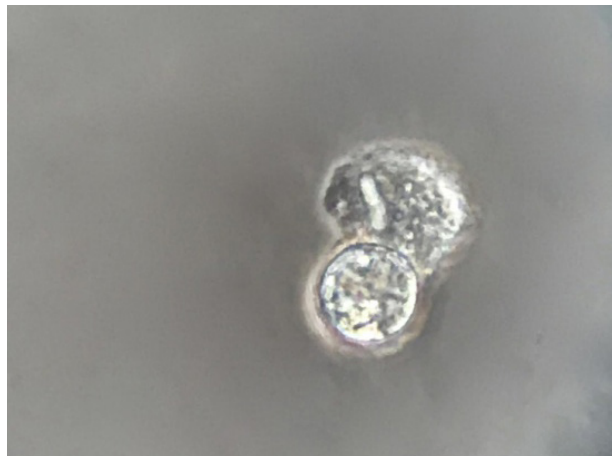
**Figure 1**

400x phase-contrast



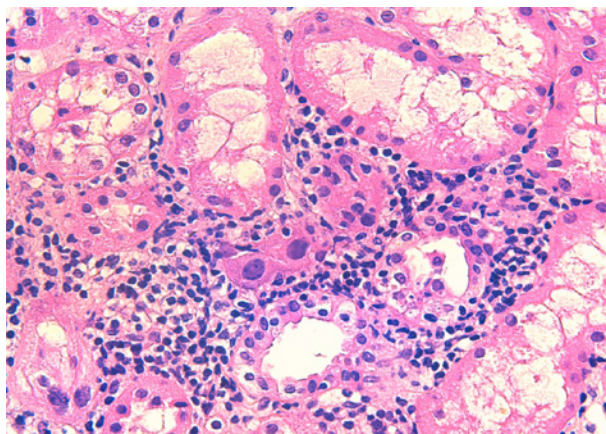
**Figure 2**

400x phase-contrast



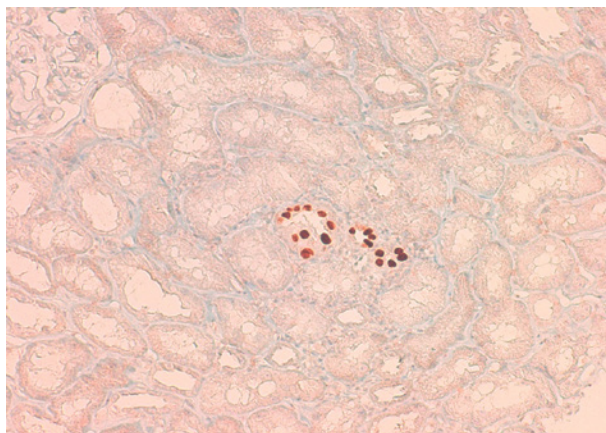
**Figure 3**

400x hematoxylin eosin



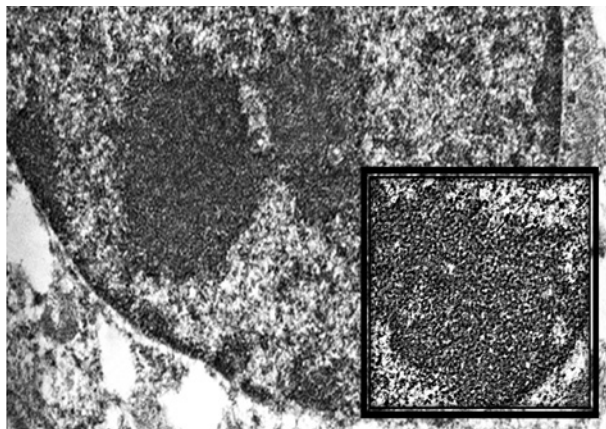
**Figure 4**

200x



**Figure 5**

15.000x paraffin embedded tissue



## ■ QUESTIONS

1. According to the clinical, blood and urinary findings, what is the most likely diagnosis?
2. What are the main morphologic features of this disease and what is the target of the positive immunohistochemistry test?
3. What treatment options do we have in this case?

## ■ ANSWERS

1. According to the clinical, blood and urinary findings, what is the most likely diagnosis?

Polyomavirus nephropathy (PVN). The suspicion of the diagnosis is supported by the identification of decoy cells (figure 1 and 2) on analysis of urinary sediment, PV viremia and increased creatinine.

PVN is a common opportunistic viral infection of renal allografts with most cases occurring in the first year after transplantation.<sup>1</sup> PV infection is near ubiquitous with peak seroprevalence in early childhood (60%-100%).<sup>2</sup> PV virus is known to persist in the reno-urinary tract with intermittent reactivation and low-level viremia in 5%-10% of immunocompetent adults. In these cases viral replication is efficiently controlled and has no clinical manifestation.<sup>3</sup> In immunocompromised individuals, PV virus reactivates and replicates triggering a cascade of events leading to tubular cell lysis and viremia.<sup>4</sup> The virus is first detectable in the urine, with viremia developing several weeks later. As PV virus multiplication in the interstitium ensues, invading the allograft, the virus crosses into the peritubular capillaries, gaining access to systemic circulation, allowing for the development of viremia.<sup>4</sup> Large viremia often occurs with the appearance of urinary decoy cells.<sup>5</sup> These cells are known as 'decoy' because the irregular shape of the cell body and their enlarged nuclei mimic microscopic aspects of neoplastic cells. Phase-contrast microscopy additionally shows altered chromatin, enlarged nucleoli, cytoplasmic vacuoles and the presence of a halo.<sup>6</sup>

Routine search of urinary decoy cells is an effective screening method for PVN since this test has a negative predictive value of 100%, ruling out all negative cases.<sup>7</sup> A positive result will require an evaluation of PV viremia, as the positive predictive value (PPV) of viremia is superior to that of decoy cell search (50-60% vs 29%). PV viremia has an intermediate PPV of 40%.<sup>4</sup>

Notwithstanding, a definitive diagnosis of PVN requires histological confirmation with a renal biopsy. For this reason we performed an ultrasound guided allograft biopsy in our patient. Additionally, biopsies allow for assessment of the degree of acute and chronic tissue injury, and enable search for other renal diseases that might affect allograft function.<sup>8</sup>

2. What are the main morphologic features of this disease and what is the target of the positive immunohistochemistry test?

PVN produces a pattern of interstitial nephritis. Morphologic features include nuclear viral cytopathic changes in tubular epithelial cells: nuclear enlargement, irregularity of nuclear contour, a pattern of chromatin clumping, inclusion-like and areas with a "ground-glass" appearance. In some cases it is possible to identify detached epithelial cells with nuclear cytopathic changes within tubular lumens. Interstitial inflammation is a common feature, accompanied by a variable degree of interstitial fibrosis. Affected areas are frequently sharply demarcated from the surrounding parenchyma.<sup>9</sup> Cellular infiltration to the interstitium and tubules of PVN are overlapping histological features of allograft rejection. This can pose a challenge to distinguish among both entities, which have opposing treatments. Immunohistochemistry can be of help since cells infected with PVN will be positively marked by monoclonal SV40-T-antibody staining.<sup>10</sup>

In 2017, in an attempt to develop a clinically relevant morphologic classification for PVN, the Banff Working Group published a new histopathologic classification based on data from the largest systematic analysis of definitive PVN cases (192 patients). Histological features with the most significant clinical correlations included both intrarenal PV load levels and Banff interstitial fibrosis ci scores. The PVN classification in three classes is based on these features, and correlates with serum creatinine levels over 24 months of follow-up, and graft failure.<sup>8</sup>

Additionally, changes in ultrastructural features evaluated by electron microscopy plays an important role in establishing a definitive PVN diagnosis, by identifying the presence of PV virions. The viral particles appear as 30-50 nm, non-enveloped particles, often arranged in paracrystalline arrays or in clusters (Figure 5), predominantly found in tubular cells.<sup>11</sup>

### 3. What treatment options do we have in this case?

There is no specific effective antiviral therapy for PVN. Therapy is based on decreasing immunosuppression. To date there is no consensus on which class of immunosuppression should first be reduced. In this case, in addition to early administration of leflunomide, which exerts an antiviral effect by disrupting virion assembly, we discontinued the antimetabolite completely and further decreased the dose of tacrolimus after allograft biopsy. Resolution of viremia can take up to several months and we expect the patient to improve.

Alas, decreasing immunosuppression is not always effective. If there is no further improvement of renal function in the following months, administration of intravenous immune globulin (IVIG) remains an option to be considered. IVIG contains BKV neutralizing antibodies against all major genotypes. The efficacy of this approach remains, nevertheless, controversial.<sup>12</sup>

Additional unproven therapies include cidofovir – a nucleotide analog of cytosine that is active against various DNA viruses, including CMV.<sup>13</sup> However, cidofovir has a nephrotoxic profile, and proteinuria and worsening kidney function have been reported in up to 20% of cases, making it therefore, a last-resort strategy.<sup>14</sup>

While it has been largely assumed that quinolone antibiotics could decrease PVN activity in the past, two randomized trials have shown that there is no added benefit to the use of levofloxacin.<sup>15,16</sup>

Overall, PVN is a significant cause of graft loss in kidney transplant patients and treatment remains unsatisfactory. While the only strategy that has shown consistent results is immunosuppression reduction, the development of an effective direct antiviral drug is highly desired.

**Disclosure of potential conflicts of interest:** None declared.

### References

- Sharif A, Alachkar N, Bagnasco S, Geetha D, Gupta G, Womer K, Arend L, Racusen L, Montgomery R, Kraus E. Incidence and outcomes of BK virus allograft nephropathy among ABO- and HLA-incompatible kidney transplant recipients. *Clin J Am Soc Nephrol*. 2012 Aug 1;7(8):1320-7.
- Replogue MD, Storch GA, Clifford DB. BK virus: a clinical review. *Clin Infect Dis*. 2001 Jul 15;33(2):191-202.
- Ramos E, Drachenberg CB, Wali R, Hirsch HH. The decade of polyomavirus BK-associated nephropathy: state of affairs. *Transplantation*. 2009 Mar 15;87(5):621-30.
- Sawinski D, Goral S. BK virus infection: an update on diagnosis and treatment. *Nephrol Dial Transplant*. 2015 Feb 1;30(2):209-17.
- Drachenberg C, Hirsch HH, Papadimitriou JC, Mozafari P, Wali R, McKinney JD, Nogueira J, Cangro CB, Mendley S, Klassen DK, Ramos E. Cost efficiency in the prospective diagnosis and follow-up of polyomavirus allograft nephropathy. *Transplant Proc*. 2004 Dec 1;36(10):3028-31.
- Fogazzi GB, Furione M, Saglimbeni L, Gatti M, Cantù M, Tarantino A. BK and JC polyomavirus infection in a patient with chronic lymphocytic leukaemia and renal failure. *Nephrol Dial Transplant*. 2002 Aug 1;17(8):1534-6.
- Hirsch HH, Knowles W, Dickenmann M, Passweg J, Klimkait T, Mihatsch MJ, Steiger J. Prospective study of polyomavirus type BK replication and nephropathy in renal-transplant recipients. *N Engl J Med*. 2002 Aug 15;347(7):488-96.
- Nickeleit V, Singh HK, Randhawa P, Drachenberg CB, Bhatnagar R, Bracamonte E, Chang A, Chon WJ, Dadhania D, Davis VG, Hopfer H. The Banff Working Group Classification of Definitive Polyomavirus Nephropathy: Morphologic Definitions and Clinical Correlations. *J Am Soc Nephrol*. 2018 Feb 1;29(2):680-93.
- Howell DN, Smith SR, Butterly DW, Klassen PS, Krigman HR, Burchette Jr JL, Miller SE. Diagnosis and management of BK polyomavirus interstitial nephritis in renal transplant recipients. *Transplantation*. 1999 Nov 15;68(9):1279-88.
- Yamanaka K, Oka K, Nakazawa S, Hirai T, Kishikawa H, Nishimura K, Kyo M, Ichikawa Y. Immunohistochemical features of BK virus nephropathy in renal transplant recipients. *Clin Transplant*. 2012 Jul;26:20-4.
- Herrera GA, Veeramachaneni R, Turbat-Herrera EA. Electron microscopy in the diagnosis of BK-polyoma virus infection in the transplanted kidney. *Ultrastruc Pathol*. 2005 Jan 1;29(6):469-74.
- Randhawa P, Brennan DC. BK virus infection in transplant recipients: an overview and update. *Am J Transplant*. 2006 Sep;6(9):2000-5.
- Kuypers DR, Vandooren AK, Lerut E, Evenepoel P, Claes K, Snoeck R, Naesens L, Vanrenterghem Y. Adjuvant low-dose cidofovir therapy for BK polyomavirus interstitial nephritis in renal transplant recipients. *Am J Transplant*. 2005 Aug;5(8):1997-2004.
- Bagnis C, Izzidine H, Deray G. Renal tolerance of cidofovir. *Therapie*. 1999;54(6):689-91.
- Lee BT, Gabardi S, Grafals M, Hofmann RM, Akalin E, Aljanabi A, Mandelbrot DA, Adey DB, Heher E, Fan PY, Conte S. Efficacy of levofloxacin in the treatment of BK viremia: a multicenter, double-blinded, randomized, placebo-controlled trial. *Clin J Am Soc Nephrol*. 2014 Mar 7;9(3):583-9.
- Knoll GA, Humar A, Fergusson D, Johnston O, House AA, Kim SJ, Ramsay T, Chassé M, Pang X, Zaltzman J, Cockfield S. Levofloxacin for BK virus prophylaxis following kidney transplantation: a randomized clinical trial. *Jama*. 2014 Nov 26;312(20):2106-14.

### Correspondence to:

Nuno Moreira Fonseca, MD, MA  
Nephrology Department, Hospital Curry Cabral, Centro Hospitalar  
Universitário de Lisboa Central, Lisboa, Portugal  
E-mail: nuno.mf@nyu.edu