

Acute kidney injury in an HIV and HCV patient

Helena Sousa Viana, Isabel Mesquita, Joaquim Calado, Fernando Nolasco, Fernanda Carvalho

Nephrology Department, Hospital de Curry Cabral, Centro Hospitalar de Lisboa Central. Lisboa, Portugal

■ CLINICAL PRESENTATION

In 1996, a 37-year-old-man with a past of IV drugs addiction was diagnosed with HCV and HIV₁, when hospitalized for pulmonary tuberculosis. After the discharge, the patient refused antiretroviral therapy.

In 2009, he initiated a therapy for his heroin addiction; a substitution programme with methadone. In September 2011, he agreed to go to infectious disease consultation. He presented an HIV charge of 100.632 copies and 2% of CD4+. He had a normal kidney function (urea of 20 mg/dl and creatinine of 1.0 mg/dl and urine type 2 without alterations). He did not have type 2 diabetes *mellitus* or hypertension. He was treated with co-trimexazole, tenofovir, emtricitabina and atazanavir.

One month later, the patient went to the emergency room for acute gastroenteritis. He presented

severe signs of dehydration and oliguria. The serum analyses demonstrated normoglycaemia, acute renal failure (urea of 83 mg/dl and creatinine of 6.7 mg/dl). Urinalysis showed eritrocituria (++) , glycosuria (150 mg/dl) and proteinuria (100 mg/dl). The 24-hour urine study revealed: proteinuria of 2363 mg/24 hours and glycosuria of 4984 mg/24 hours. Electrophoresis of serum proteins and the serum complement, C₃ and C₄, were normal. Electrophoresis of urinary proteins disclosed glomerular and tubular proteinuria. The renal echography revealed normal kidneys. A kidney biopsy was performed.

■ HISTOLOGICAL DIAGNOSIS

Figure 1 shows a large area of acute necrosis which extends to all the cortex. The proximal tubules show

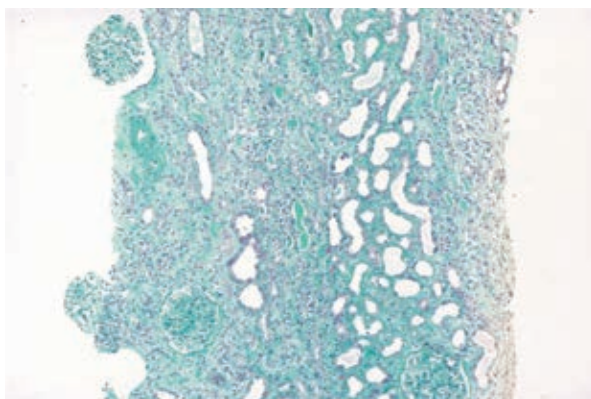


Figure 1
Masson Trichrome green, (X100).

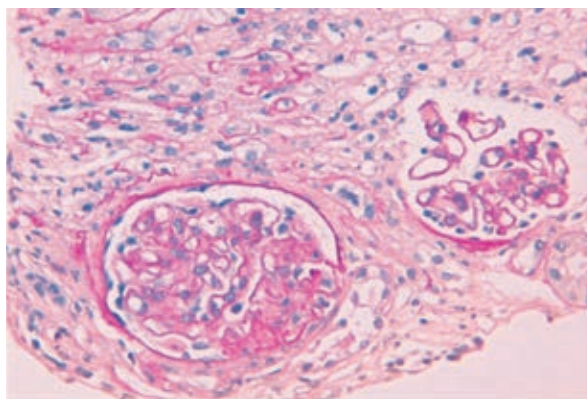


Figure 2
Periodic acid-Schiff, (X400).

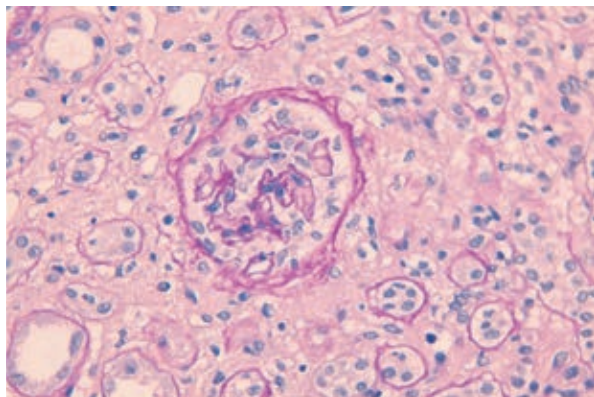


Figure 3
Periodic acid-Schiff, (X400).

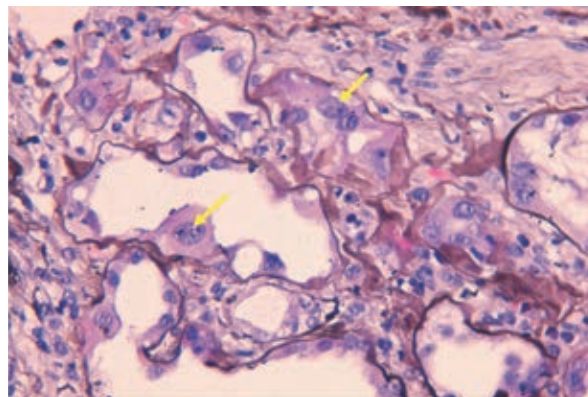


Figure 5
Silver methenamine, (X400).

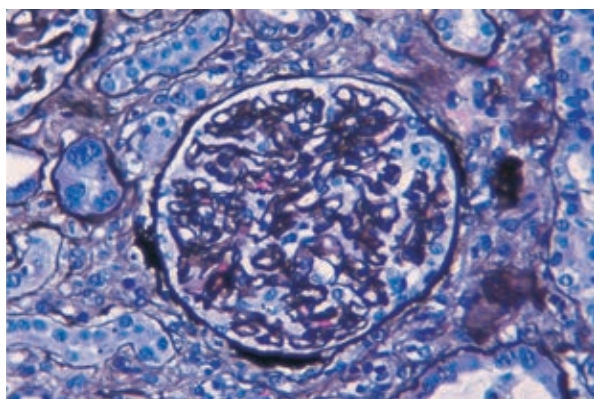


Figure 4
Silver methenamine, (X400).

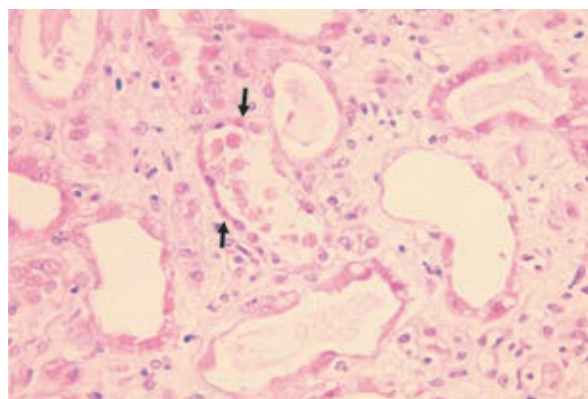


Figure 6
Haematoxylin-eosin, (X400).

loss brush borders and apical cytoplasm. In some areas, we can even see the denudation of tubular epithelial cells. We see strips of interstitial fibro-oedema switching with strips of established fibrosis. A mononuclear inflammatory infiltrate of medium intensity is visible.

Figure 2 shows two glomeruli surrounded by interstitial fibrosis. Both glomeruli have a slightly ischaemic appearance. The glomerulus in the left presents a sclerosed segmentar lesion.

In **Figures 3 and 4**, another glomerulus encircled by interstitial fibrosis and tubular atrophy shows podocytes hypertrophy and hyperplasia.

In **Figure 5**, we can see (arrow) karyomegaly with nuclear enlargement, hyperchromatism and coarse nucleoli.

Figure 6 presents proximal tubular eosinophilic cytoplasmic inclusions (arrow) (megamitochondria).

■ DIAGNOSIS

Tenofovir nephrotoxicity
Podocytopathy of HIV

■ DISCUSSION

Tenofovir is the unique reverse transcriptase inhibitor of HIV 1 approved by FDA and is widely used in antiretroviral regimens on the basis of its efficacy and tolerability. The first clinical trials do not reveal nephrotoxicity, however, numerous cases reports and case series report¹ tubular renal dysfunction. Nearly 15% of patients treated with tenofovir for 2-9 years develop renal tubular dysfunction². The main site of tenofovir tubular lesions is the proximal tubule and the principal manifestations are Fanconi syndrome and acute kidney injury³. The drug inhibits mitochondria DNA polymerase, which decreases mitochondrial DNA (mtDNA) replication. This has been related (C) to structural mitochondrial abnormalities, some of them visible in optical microscopy: mitochondrial depletion, wide change of size, loss or disorientation of cristae.

The hyperplasia /hypertrophy of podocytes and the glomerulosclerosis lesion were probably consequence of the direct HIV lesion and explain the glomerular proteinuria associated.

■ TREATMENT AND EVOLUTION

Tenofovir was discontinued and another anti-retroviral scheme was started.

The patient started haemodialysis, and progressively recovered diuresis. Dialysis was stopped after 3 sessions.

In the latest follow-up, the patient presented a creatinine of 2.4 mg/dl and a urine type 2 without proteinuria or glycosuria.

Conflict of interest statement: *None declared*

References

1. Mesquita I, Viana H, Casimiro I, Calado J, Carvalho F, Nolasco F. Nefrotoxicidade ao tenofovir – revisão de 3 casos clínicos. *Port J Nephrol Hypert* 2013; 27 (Suppl. 1): 48
2. Quinn KJ, Emerson CR, Dinsmore WW, Donnelly CM. Incidence of proximal renal tubular dysfunction in patients on tenofovir disoproxil fumarate. *Int J STD AIDS* 2010;21(2):150-151
3. Fernandez-Fernandez B, Montoya-Ferrer A, Sanz AB, *et al.* Tenofovir nephrotoxicity: 2011 update. *AIDS Res Treat* 2011; doi: 10.1155/2011/354908.
4. Herlitz LC, Mohan S, Stokes MB, Radhakrishnan J, D'Agati VD, Markowitz GS. Tenofovir nephrotoxicity: acute tubular necrosis with distinctive clinical, pathological, and mitochondrial abnormalities. *Kidney Int* 2010;78(11):1171-1177.

Correspondence to:

Dr^a Helena Viana
Department of Nephrology, Hospital Curry Cabral
Rua da Beneficência, nº8, 1069-166
Lisboa, Portugal
E-mail: viana.helena@gmail.com