

Results of endovascular procedures performed in dysfunctional arteriovenous accesses for haemodialysis

Susana Machado¹, Aníbal Ferreira², Carlos Lucas³, Célia Gil³, Alice Fortes⁴, Fernando C. Neves⁴

¹ Nephrology Department, Hospitais da Universidade. Coimbra, Portugal.

² Nephrology Department, Hospital Curry Cabral. Lisboa, Portugal.

³ Nephrology Department, Hospital de Santa Cruz. Carnaxide, Portugal.

⁴ Nephrology Department, Hospital de Santa Maria. Lisboa, Portugal.

Received for publication: 14/01/2012

Accepted in revised form: 18/09/2012

■ ABSTRACT

Aim. Percutaneous endovascular procedures have become the standard treatment of arteriovenous fistulae and graft stenosis. This study evaluates the immediate results of angiographic procedures performed by nephrologists in patients with dysfunctional arteriovenous fistulae and arteriovenous graft stenosis.

Patients and Methods. A retrospective analysis was performed on patients referred to the three Interventional Nephrology units between April and June, 2010. Clinical data were recorded.

Results. A total of 113 procedures were performed: 59 in arteriovenous fistulae and 54 in arteriovenous graft stenosis. The main reasons for referral were increased venous pressure (21%), limb oedema (21%) and decreased intra-access flow (20%). Stenoses were detected in 85% of the procedures, mostly in patients with arteriovenous graft stenosis (56%). The main locations of stenosis were the outflow vein (cephalic/basilic) in arteriovenous fistulae (34%) and venous anastomosis in arteriovenous graft stenosis (48%). Angioplasty was performed in 73% of procedures where stenoses were detected. The immediate success rate was 91% for arteriovenous fistulae and 83% for arteriovenous graft stenosis. Partial success

was obtained in 11% of angiographies. The complication rate was 7%.

Conclusions. Physical examination findings led, in at least half the cases, to angiography referral and enabled the diagnosis and treatment of stenoses. For this reason, we advocate that this tool should be included in any vascular access monitoring programme. Our results support the safety of these procedures performed by nephrologists and their efficacy in the recovery of dysfunctional arteriovenous fistulae and arteriovenous graft stenosis.

Key-Words:

Angiography; haemodialysis; vascular access stenosis.

■ INTRODUCTION

Interventional Nephrology is an area which deals with diagnostic and therapeutic techniques of dialysis vascular access, including percutaneous endovascular procedures performed to manage arteriovenous fistulae (AVF) and polytetrafluoroethylene arteriovenous graft (AVG) dysfunction¹. Traditionally, haemodialysis vascular access-related procedures have been almost exclusively performed by surgeons and interventional

radiologists. However, several published studies show that nephrologists are able to perform them safely and with excellent results². Advantages include less delay between detection of access dysfunction and angiographic procedure, less hospital admissions and less short-term central venous catheter placement³. Moreover, the nephrologist is in a privileged position because he is in daily contact with vascular access problems and fully understands their importance in end-stage kidney disease patients.

The aim of this study was to evaluate the immediate results of angiographic procedures performed by nephrologists in patients with dysfunctional AVF and AVG.

■ PATIENTS AND METHODS

This retrospective study enrolled 113 angiographic procedures performed in 105 patients with stage 5 chronic kidney disease (97 patients on haemodialysis and 8 predialysis patients), referred to three Interventional Nephrology units between April 1 and June 30, 2010. The patients were distributed as follow: Hospital Santa Maria (n=49), Hospital Santa Cruz (n=35) and Hospital Curry Cabral (n=21). The following variables were analysed: gender, age, type and location of vascular access, referral cause, number and location of the stenoses detected, number of percutaneous angioplasties (PTA) performed, immediate success rate of the intervention and complications.

The puncture site of the vascular access was based on the referral cause and on physical examination findings. Thus, in AVF, the diagnostic angiography was performed by anterograde (n=38) and retrograde (n=4) venous approach or by puncturing the brachial artery (n=17). Anterograde and retrograde puncture was chosen for AVG assessment in 51 and 3 procedures, respectively. Based on the stenosis location, balloons of 4 to 12 mm in diameter were used for PTA performance and inflated to the maximum pressure specified by the manufacturer. Anatomic, haemodynamic or clinical success was defined in agreement with the reporting standards of the (American) Society of Interventional Radiology⁴.

All data was analysed using the SPSS software program (version 17.0, SPPS, Chicago, IL, USA).

Numerical variables are shown as mean and standard deviation. Fisher's exact test was used for the comparison of categorical variables. A *p* value < 0.05 was considered statistically significant.

■ RESULTS

We analysed 105 patients, 56 male (M) and 49 female (F), with a mean age of 60.2±16.6 years (range 19-89 years), mostly on dialysis (n=97). Throughout the three-month study, almost all patients (n=99) were referred only once to angiographic study. Five patients were referred twice, and one patient recorded a total of four procedures. These patients underwent a total of 113 procedures, 59 in AVF and 54 in AVG. At least one stenosis was detected in 88 assessments (85%).

■ Arteriovenous fistulae

Fifty-nine procedures were performed in 56 patients with AVF (39M/17F) mean age 61.2±16.2 years.

The location of the AVF was radiocephalic (n=17), brachiocephalic (n=33) and brachio basilic (n=9). In radiocephalic fistulae, the angiographic exam was most often driven by delayed maturation (n=7) or decrease of the intra-access flow (n=7). In the brachiocephalic fistulae, increased venous pressure (n=11) and pulsatility of access (n=6) were the main referral causes. Limb oedema (n=2) and a reduction in intensity of the thrill (n=2) were the principal physical changes that led to the performance of the procedure in brachio basilic fistulae.

Significant stenoses were encountered in 39 exams (66%) performed in patients with AVF and the main reasons for referral to angiographic study in these patients are listed in Table I. In 25 cases we found an isolated stenosis. Two (n=9), three (n=4) or four (n=1) stenoses were found in the remaining exams. The lesions were detected in peripheral (n=29) or central veins (n=6) and less often in both locations (n=4).

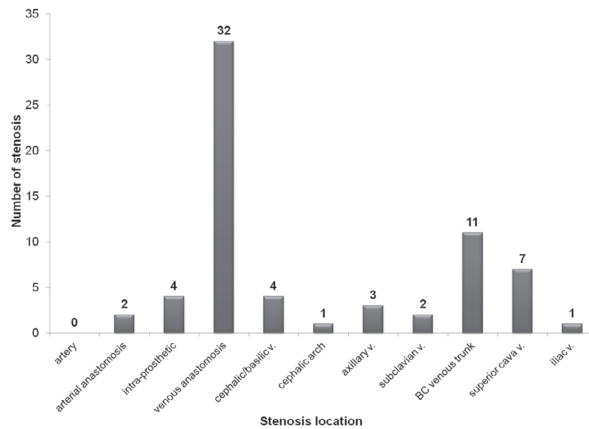
Stenoses in AVF were found mostly in the outflow vein (cephalic/basilic) (n=20) and perianastomotic area (n=13) (fig. 1). Cephalic arch stenosis was detected in 8 angiographies performed to evaluate

Table 1

Reason for angiography referral in vascular access with stenosis

Referral cause	AVF		AVG	
	No. of exams	%	No. of exams	%
Increased venous pressure	8	21	11	22
Decreased intra-access flow	8	21	10	21
Ipsilateral limb oedema	6	15	17	35
Vascular access pulsatility	6	15	5	10
Deficient maturation	4	10	0	0
Post-thrombectomy control	0	0	4	8
Difficulty in puncture	2	5	2	4
Collateral circulation	1	3	0	0
Decreased dialysis dose	1	3	0	0
Others	3	7	0	0
Total	39	100	49	100

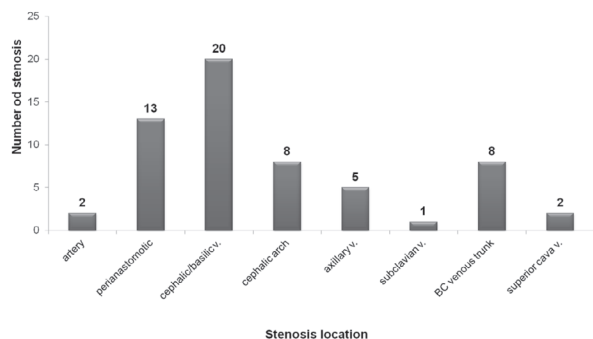
AVF: arteriovenous fistulae. AVG: arteriovenous graft



V: vein; BC: brachiocephalic

Figure 2

Location of the stenosis found in patients with arteriovenous grafts (n=67)



V: vein; BC: brachiocephalic

Figure 1

Location of the stenosis found in patients with arteriovenous fistulae (n=59)

AVF: 6 in brachiocephalic and 2 in radiocephalic AVF. In brachiocephalic AVF, the overall prevalence of cephalic arch stenosis was 26%.

Arteriovenous grafts

Fifty-four procedures were performed in 49 patients with AVG (17M/32F), mean age 59.2±17.3 years (range 19-85 years). The vascular graft was located between the brachial artery and axillary vein in 46 patients, the femoral artery and vein in 2 patients and 1 patient had a brachiocephalic graft.

At least one stenosis was found in 49 examinations performed in patients with AVG (91%). Therefore, there was a higher rate of stenosis detection in patients with AVG than those with AVF (91% vs. 66%, p = 0.005). The main reasons for referral to angiographic study are listed in Table 1.

Once again, in the majority of the procedures, a single stenotic lesion was encountered (65%). Two stenoses were detected in 16 cases (33%) and three simultaneous lesions were found in one case (2%). The stenoses were mostly in peripheral (57%) or central (29%) veins. Seven patients (14%) had stenoses in both locations.

In AVG, the stenotic lesions prevailed in the venous anastomosis (48%) (Fig 2.). A cephalic arch stenosis was detected in one patient with a brachiocephalic graft.

Angioplasty

Angioplasty was carried out in 64 cases (22 in AVF/42 in AVG). The overall immediate success rate was 91% for AVF (n=20) and 83% in AVG (n=35). In AVG, 7 angioplasties were performed with only partial success (residual stenosis > 30%) because of the following reasons: interruption of the exam due to poor patient collaboration (n=1) or onset of complications (n=3); failure in stent placement due to

the location of the stenosis (n=2); and significant deterioration of prosthetic material (n=1).

In radiocephalic fistulae stenosis, only 18% of PTA (n=2) were performed, with a 50% success rate. In the upper arm fistulae stenoses, PTA was performed in 71% of cases, with an overall success rate of 95%. All patients with cephalic arch stenosis underwent PTA of the lesion with total success and without complications.

In one patient with AVG, a stent (Wallstent, Boston Scientific® USA) was placed due to elastic recoil.

■ Complications

The overall complication rate was 7%. Four events occurred in patients with AVF procedures: mild allergic reaction (n=2), vomiting (n=1) and access thrombosis (n=1). The interventions in patients with AVG complicated with minor disruption of the vessel (n=2), extensive haematoma (n=1) and supraventricular tachycardia (n=1).

■ DISCUSSION

When comparing the type of haemodialysis vascular access, the AVF is the one which shows a lower rate of thrombosis and infection, a lower number of hospital admissions and is associated with a greater patient survival. Due to all these advantages, the AVF is regarded as the preferred vascular access by the KDOQI guidelines (2006). AVG placement should be considered in the following conditions: absence of vascular capital or high probability of poor AVF maturation⁵.

The most common cause of vascular access dysfunction is venous stenosis and is primarily due to venous neointimal hyperplasia in both AVG and fistulae⁶. Venous stenosis in vascular accesses is characterised by (a) the presence of alpha smooth muscle actin positive cells and myofibroblasts, (b) neovascularisation within the neointima and adventitia, (c) a macrophage layer lining the perigraft region (AVG), (d) the presence of cytokines, such as platelet derived growth factor, vascular endothelial growth factor and basic fibroblast growth factor

and (e) the expression of matrix proteins such as collagen and tenascin⁶.

In AVF, the stenosis is highly influenced by the vasodilatory capacity of the vein and surgical technique. The process of neointimal hyperplasia formation is complex and includes two main events. An initial injury of the endothelium and smooth muscle occurs followed by the migration of smooth muscle cells and myofibroblasts from the media into the intima, where they proliferate and form the stenotic lesion^{7,8}. Some triggering factors have been identified: (a) haemodynamic stress at the artery-vein or graft-vein anastomosis due to a combination of low shear stress, turbulence and compliance mismatch, (b) surgical injury at the time of construction of the vascular access, (c) attraction of inflammatory cells to the graft itself, (d) graft injury caused by insertion of dialysis needles, (e) uraemia which has been shown to exacerbate endothelial dysfunction and (f) genetic predisposition of veins to vasoconstriction and neointimal hyperplasia^{7,8}.

In this study, the detection of stenoses was more common on angiographic examinations performed in patients with AVG than with AVF (91% vs. 66%), which is in agreement with published literature⁵.

As would be expected, the perianastomotic area was the most common location of AVF stenosis (31% of cases) and resulted from the devascularisation of the vein wall during surgical dissection⁹. More than half the stenoses in AVG occurred in the venous anastomosis, where the susceptibility for stenotic lesions is higher due to neointimal hyperplasia.

The cephalic arch stenosis seems to have a distinct functional profile from other venous stenoses. In this study, 9 stenotic lesions were found in the cephalic arch, most of them in patients with brachiocephalic vascular access (78%). Published data point to a prevalence of cephalic arch stenosis between 4.25 and 64%, in patients with brachiocephalic fistulae¹⁰. Some potential factors explain this high prevalence. The portion of the cephalic arch that is located directly beneath the clavicular head of the pectoralis major muscle and the portion that pierces the clavicular fascia might be under extrinsic compression and halt remodelling of this venous segment. The cephalic arch possesses valves that may interfere with dilation after fistulae creation. Additionally, haemodynamic

forces, due to high blood flow rates, make this segment particularly prone to injury¹¹.

The 2006 KDOQI guidelines recommend monitoring of the vascular access by direct measurement of intra-access blood flow (in AVF and AVG) and determination of venous pressure (AVG) (Evidence A). The physical examination of the vascular access is considered, in these guidelines, to be an Evidence B recommendation. However, in our study, in more than half the exams in which stenoses were detected, the cause for referral was based on clinical findings. This demonstrates that the physical examination should not be neglected by the nephrologist and is a useful tool for detecting vascular access problems that can be corrected in a timely manner.

Eight angiograms were performed after surgical thrombectomy (1 exam in AVF and 7 in AVG) leading to higher financial costs. There is no accepted method for carrying out vascular access thrombectomy. Some studies suggest that surgical revision of the vascular access provides better long-term patency¹², while others show that angioplasty results are comparable to those of surgical revision¹³. However, angioplasty has additional advantages to be considered, such as less invasiveness, shorter procedure time, shorter hospital stays and fewer anaesthetic requirements.

The angiographic assessment was important in the studied population because it allowed for the detection of stenoses in 85% of the procedures and enabled therapeutic intervention in more than 70% of the cases. The overall immediate success rate of PTA was 91% for AVF and 83% for AVG. These findings are consistent with published data by Turmel-Rodrigues *et al.*¹⁴, Parreira *et al.*¹⁵ and Surlan *et al.*¹⁶, but slightly lower than those reported by other authors such as Beathard¹⁷ and Patanè *et al.*¹⁸.

The primary and secondary patency rates were not possible to evaluate due to logistical reasons. Nevertheless, follow up data indicated that 8% of patients with vascular access stenosis underwent reintervention within the 3 months of the data collection. In fact, the great need for reinterventions after angioplasty is very often a comment in most trials into endovascular percutaneous treatment outcomes^{19,20}.

The complication rate depends on the centre's experience and, in published studies, ranges from 1.7 to 14.9%²¹⁻²³. In this study, complications occurred in 7% of the procedures, without considerable severity. The two cases of vessel rupture were easily addressed with a second balloon inflation.

CONCLUSION

This study highlights the importance of the physical examination findings that led, in at least half the cases, to the performance of angiographic procedures and enabled the diagnosis and treatment of stenoses. For this reason, the authors advocate that physical examination should be included in any vascular access monitoring programme, complementing the more objective methods currently available. The results presented in this study support the safety of these procedures performed by nephrologists and their efficacy in the recovery of dysfunctional arteriovenous fistulae and grafts.

Conflict of interest statement. None declared.

References

1. Efstratiadis G, Platsas I, Koukoudis P, Vergoulas G. Interventional Nephrology: a new subspecialty of Nephrology, *Hippokratia* 2007;11:22-24
2. Beathard GA, Litchfield T. Effectiveness and safety of dialysis vascular access procedures performed by interventional nephrologists. *Kidney Int* 2004;66:1622-1632
3. Asif A, Merrill D, Briones P, Roth D, Beathard GA. Hemodialysis vascular access: percutaneous interventions by nephrologists. *Semin Dial* 2004;17:528-34
4. Gray R, Sacks D, Martin L, *et al.* Technology Assessment Committee of the Society of Interventional Radiology. Reporting standards for percutaneous interventions in dialysis access. *J Vasc Interv Radiol* 2003;10:1405-1415
5. K/DOQI Clinical Practice Guidelines and Clinical Practice Recommendations 2006 Updates Hemodialysis adequacy Peritoneal Dialysis Adequacy Vascular Access. *Am J Kidney Dis* 2006;48(Suppl1):S176-S273
6. Budu-Grajdeanu P, Schugart R, Friedman A, *et al.* A mathematical model of venous neointimal hyperplasia formation. *Theor Biol Med Model* 2008;23:2
7. Lee T, Roy-Chaudhury P. Advances and New Frontiers in the Pathophysiology of Venous Neointimal Hyperplasia and Dialysis Access Stenosis. *Adv Chronic Kidney Dis* 2009;16:329-338
8. Roy-Chaudhury P, Sukhatme V, Cheung A. Hemodialysis Vascular Access Dysfunction: A Cellular and Molecular Viewpoint. *J Am Soc Nephrol* 2006;17:1112-27
9. Konner K, Gersch M. Vascular Access for Hemodialysis In: Feehally J, Floege J, Johnson R (eds). *Comprehensive Clinical Nephrology*, third edition, Mosby Inc 2007, pp929-940
10. Roca-Tey R, Samón R, Ibrik O, *et al.* Perfil funcional de la estenosis del arco de la vena cefálica. *Nefrología* 2009;29:350-353

11. Salman L, Asif A. Stent graft for nephrologists: concerns and consensus. *Clin J Am Soc Nephrol* 2010;5:1347-1352
12. Ko P. Surgical thrombectomy for thrombosed dialysis grafts: comparison of adjunctive treatments. *World J Surg* 2008;32:241-245
13. Kao T, Liu Y, Hsieh M, *et al.* Ballon angioplasty versus surgical revision for thrombosed dialysis graft outlet stenosis after graft thrombectomy. *Angiology* 2010;61:580-583
14. Turmel-Rodrigues L. Dilatation and declotting of arteriovenous accesses. *The Apher Dial* 2003;7:244-251
15. Parreira L, Matias P, Amaral T, *et al.* Endovascular treatment of dysfunctional arteriovenous fistulas and grafts: results from a single centre. *Port J Nephrol Hypert* 2009;23:245-247
16. Surlan M, Popovic P. The role of interventional radiology in management of patients with end-stage renal disease. *Eur J Radiol* 2003;46:96-114
17. Beathard GA. Percutaneous transvenous angioplasty in the treatment of vascular access stenosis. *Kidney Int* 1992;42:1390-1397
18. Patanè D, Morale W, Malfa P, *et al.* Steno-obstructions of haemodialytic FAV: new aspects of endovascular treatment. *G Ital Nefrol* 2009;26:236-245
19. Kim YC, Won JY, Choi SY, *et al.* Percutaneous treatment of central stenosis in hemodialysis patients: long-term outcomes. *Cardiovasc Intervent Radiol* 2009;32:271-278
20. Beathard GA. Angioplasty for arteriovenous grafts and fistulae. *Semin Nephrol* 2002;22:202-210
21. Tessitore N, Mansueto G, Bedogna V, *et al.* A prospective controlled trial on effect of percutaneous transluminal angioplasty on functioning arteriovenous fistulae survival. *J Am Soc Nephrol* 2003;14:1623-1627
22. Turmel-Rodrigues L, Pengloan J, Baudin S, *et al.* Treatment of stenosis and thrombosis in haemodialysis fistulas and grafts by interventional radiology. *Nephrol Dial Transplant* 2000;15:2029-2036
23. Natário A, Turmel-Rodrigues L, Fodil-Cherif M, *et al.* Endovascular treatment of immature, dysfunctional and thrombosed forearm autogenous ulnar-basilic and radial-basilic fistulas for haemodialysis. *Nephrol Dial Transplant* 2010;25:532-538

Correspondence to:

Dr Susana Machado
Department of Nephrology
Hospitais da Universidade de Coimbra
Praceta Professor Mota Pinto,
3000-075 Coimbra
Portugal
E-mail: susana_machado_@hotmail.com