

Clinical and pathological findings in women with Fabry disease

Ana Natário^{1,2}, Helena Viana², Maria João Galvão², Fernanda Carvalho²

¹ Nephrology Department, Centro Hospitalar de Setúbal. Setúbal, Portugal.

² Renal Pathology Laboratory, Nephrology Department, Hospital Curry Cabral. Lisbon, Portugal.

Received for publication: 29/12/2011

Accepted in revised form: 16/02/2012

ABSTRACT

Introduction. Fabry disease is a rare metabolic disorder caused by the genetic deficiency of the lysosomal hydrolase alpha-galactosidase A, located on chromosome X. Females with the defective gene are more than carriers and can develop a wide range of symptoms. Nevertheless, disease symptoms generally occur later and are less severe in women than in men. The enzyme deficiency manifests as a glycosphingolipidosis with progressive accumulation of glycosphingolipids and deposit of inclusion bodies in lysosomes giving a myelin-like appearance.

Patients and Methods. Records of renal biopsies performed on adults from 1st January 2008 to 31st August 2011, were retrospectively examined at the Renal Pathology Laboratory. We retrieved biopsies diagnosed with Fabry disease and reviewed clinical and laboratory data and pathology findings.

Results. Four female patients with a mean age of 49.3±4.5 (44-55) years were identified. The mean proteinuria was 0.75±0.3 g/24h (0.4-1.2) and estimated glomerular filtration rate (CKD EPI equation) was 71±15.7 ml/min/1.73m² (48-83). Three patients experienced extra-renal organ involvement (cerebrovascular, cardiac, dermatologic, ophthalmologic and thyroid) with distinct severity degrees. Leukocyte α-GAL A activity was below normal range in the four cases but plasma and urinary enzymatic activity was normal.

Light microscopy showed predominant vacuolisation of the podocyte cytoplasm and darkly staining granular inclusions on paraffin and plastic-embedded semi-thin sections. Electron microscopy showed in three patients the characteristic myelin-like inclusions in the podocyte cytoplasm and also focal podocyte foot process effacement. In one case the inclusions were also present in parietal glomerular cells, endothelial cells of peritubular capillary and arterioles.

Conclusion. Clinical signs and symptoms are varied and can be severe among heterozygous females with Fabry disease. Intracellular accumulation of glycosphingolipids is a characteristic histologic finding of Fabry nephropathy. Since this disease is a potentially treatable condition, its early identification is imperative. We should consider it in the differential diagnosis of any patient presenting with proteinuria and/or chronic kidney disease, especially if there is a family history of kidney disease.

Key-Words:

Fabry disease; glomerulopathy; renal biopsy.

INTRODUCTION

Fabry disease (FD) is a progressive, X-linked inherited disorder of glycosphingolipid metabolism due to deficient or absent lysosomal α-galactosidase A (α-GAL A) activity. This results in progressive accumulation of globotriaosylceramide (Gb₃ or GL-3) and

related glycosphingolipids within lysosomes in a variety of cell types, including capillary endothelial cells, renal, cardiac and nerve cells¹.

The incidence of Fabry disease has been estimated to be 1:117,000 overall births². The age of symptom onset and the age of diagnosis tend to be approximately 10 years later in females than males³. There is often significant delay in the diagnosis⁴.

Phenotype differences are due in part to random X-chromosome inactivation, resulting in considerable variability in α -GAL A activity among carriers and within one carrier individual among various tissues or regions of a single tissue⁴.

The classical phenotype presents with early dermatologic, ophthalmologic, and peripheral nervous system involvement. Renal, cardiac and cerebrovascular complications are major causes of morbidity and mortality in adults¹.

Renal impairment often begins with microalbuminuria and proteinuria in the second to third decade of life. Isosthenuria accompanied by alterations in tubular reabsorption, secretion and excretion also develops¹. By adulthood, renal failure frequently becomes a major complication of Fabry disease, with more than half of males eventually developing advanced renal failure or end-stage renal disease (ESRD)⁵.

Heterozygous female individuals can develop a wide range of symptoms, ranging from asymptomatic to overt disease⁶. The majority of females have slowly progressive kidney disease, but a smaller subset seem to be more seriously affected with progression to ESRD at the same median age as men⁷.

Classically, renal lesions result from Gb₃ deposition in the lysosomes of podocytes, glomerular endothelial, parietal epithelial, mesangial and interstitial cells that may lead to progressive microvascular dysfunction, occlusion and ischaemia, with subsequent development of segmental and global glomerular sclerosis, tubular atrophy and interstitial fibrosis⁸⁻¹⁰. Podocyte injury might correlate directly with proteinuria and play a pivotal role in the development and progression of Fabry nephropathy¹¹. Glycosphingolipid storage also occurs in the epithelium of the loop of Henle and the distal tubules,

and in the endothelial and smooth muscle cells of the renal arterioles¹.

Kidney biopsy may be useful as a baseline assessment and in patients with atypical presentations, including a repeat kidney biopsy when the disease is progressing despite therapy¹. In some cases, females can develop the same kidney histopathology as males^{8,12,13}.

The aim of this study is to review the clinicopathological findings of females with Fabry disease, whose renal biopsies were analysed in a single nephropathology laboratory.

■ PATIENTS AND METHODS

Four renal biopsies performed on four adult females and analysed at our institution from 1st January 2008 to 31st August 2011 were retrospectively examined.

We recorded the following data from each patient: age, gender, race, indication for renal biopsy (clinical syndrome), clinical manifestations in other organs, *GLA* gene mutation, plasma and leukocyte α -GAL A levels and urinary activity measurements.

Renal biopsy specimens were stained and analysed by light microscopy (LM), immunofluorescence (IMF) and electron microscopy (EM). Routine LM examination was performed on haematoxylin and eosin (HE), periodic acid-Schiff (PAS), Jones methenamine silver (SM), and trichrome stains (TR). Histological findings were scored by LM, with respect to glomerular and interstitial changes as 0, none; 1, mild (<25%); 2, moderate (25-50%); and 3, severe change (>50%)⁸. Vascular changes were analysed for intimal thickening and hyalinosis using the same scoring system.

We reviewed the semi-thin toluidine blue-stain sections that were prepared as survey sections for electron microscopy.

All specimens were studied by IMF using anti-immunoglobulin (A, G and M), anti-C₃, C₄, C_{1q} of complement and anti-albumin antibodies.

Electron microscopy images were reviewed in all cases.

RESULTS

Clinical findings

We retrospectively identified four female patients with Fabry disease in our renal biopsy files, and their clinical and laboratory data are summarised in Table I.

All patients were Caucasian, ranging in age from 44 to 55 years (mean 49.3±4.5). Estimated glomerular filtration rate (CKD EPI equation) was 71±15.7 ml/min/1.73m² (48-83). Three patients with a mean age of 39.3±6.0 (33-45) years were diagnosed with hypertension and, in these cases, 24-hour urine total protein (mean 0.75±0.34 g/24h) was measured while on treatment with angiotensin converting enzyme inhibitors and/or angiotensin receptor blockers.

Two patients were sisters (patients 1 and 2) and all had at least one case of first-degree family history of renal disease.

The indications for renal biopsy were non-nephrotic proteinuria in three patients and chronic renal failure with proteinuria in the other.

In three cases the diagnosis was established by biochemical and genetic studies prior to renal biopsy. Skin biopsy of angiokeratomas performed in our nephropathology centre (Fig. 1) allowed the diagnosis in one case (patient 3).

All the females had leukocyte α-GAL A activity below normal range but plasma and urinary enzymatic activity was normal.

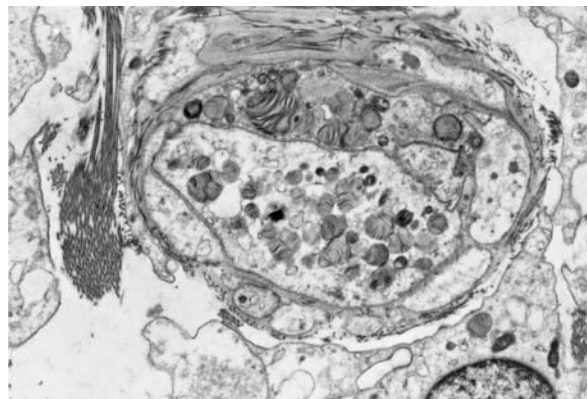


Figure 1
Electron microscopy of skin biopsy (patient 3) of a small superficial angioma showing lysosomal inclusion with myelin-like figures within endothelial cells and capillary lumen).

Clinical manifestations were provided by the patients' physicians and are shown in Table II. Cardiovascular involvement was exhibited as hypertension in three patients and also left ventricular hypertrophy in other case. Cryptogenic ischaemic stroke occurred in one patient at the age of 38 years. Ophthalmologic, cutaneous lesions, thyroid dysfunction and peripheral neuropathic pain were present in one patient. Finally, in one case the only manifestation was non-nephrotic proteinuria.

Light microscopy

On average, 10±1.6 (range 8-12) glomeruli were present for light microscopic assessment, and 2.8±1.3

Table I

Clinical and laboratory data at the time of renal biopsy

Patient	Age (years)	Serum creatinine (mg/dL)	eGFR (CKD EPI equation) (ml/min/1.73m ²)	Urine protein (g/24h)	Leukocyte α-galactosidase (Nmol/h/mg protein)	Plasma α-galactosidase (Nmol/h/mL plasma)	Urinary Gb ₃ (ug/mmol creat)	GLA gene mutation
1	49	0.9	75	0.4	20	10	8	Arg112His
2	55	0.8	83	0.6	2	5	No data	Arg112His
3	44	0.9	78	0.8	1.9	6	No data	Pro265Arg
4	49	1.3	48	1.2	27	6	2.9	ΔGlu358

* Reference range: 36-80 nmol/h/mg protein

** Reference range: 6-19 nmol/h/mL plasma

*** Reference range: <25 μmmol creat

Table II

Clinical manifestations in female Fabry disease patients

Patient	Family history	Kidney	Heart	Eyes	Skin	Nervous System	Other
1	Sister and father with FD. Father with ESRD	nonnephrotic proteinuria	–	–	–	–	–
2	Sister and father with FD. Father with ESRD	nonnephrotic proteinuria	hypertension	–	hypohidrosis	headache	breast cancer
3	Mother with FD	nonnephrotic proteinuria	hypertension left ventricular hypertrophy	cornea verticillata	angiokeratoma (trunk and thighs)	acroparesthesias	diabetes mellitus type 2 dyslipidaemia hypothyroidism
4	Brother died of CKD and renal transplantation Mother died of sudden death in the 4th decade of life	proteinuria, CKD	hypertension	–	–	ischaemic stroke hearing loss	–

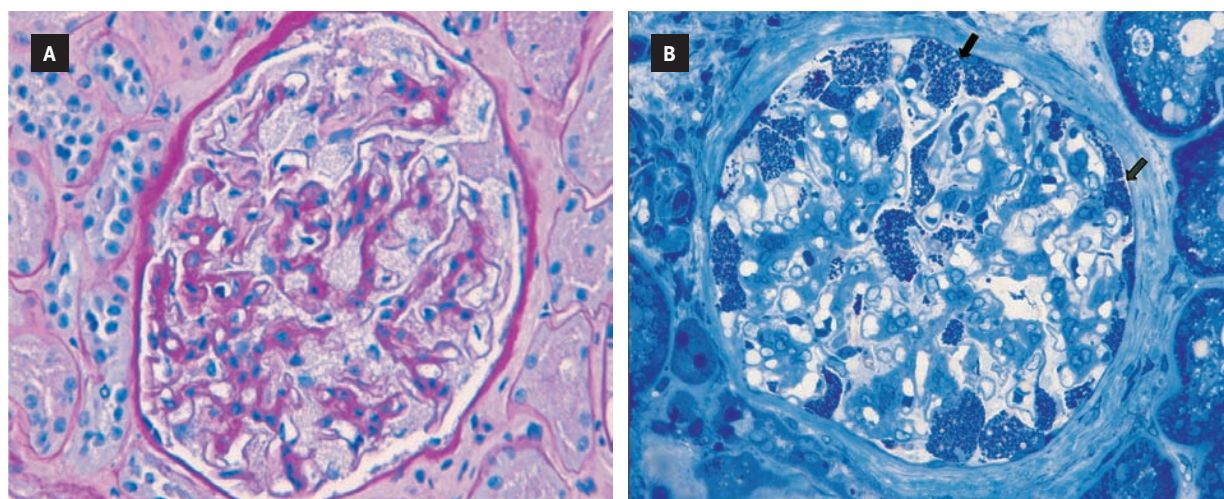
Table III

Light microscopy findings in renal biopsies

Patient	Glomeruli number	Mesangial proliferation	Ischaemic glomeruli	Foamy vacuoles on p/pg/pc/ea*	Tubular atrophy/interstitial infiltrate	Interstitial fibrosis	Glomerular sclerosis	Intimal thickening/hyalinosis	Elastic duplication
1	8	0/3	0/8	2/0/0/0	1/3	0/3	0/3	0/3	0/3
2	12	1/3	2/12	1/0/0/0	0/3	0/3	0/3	1/3	1/3
3	10	0/3	0/10	3/2/1/1	1/3	0/3	0/3	0/3	0/3
4	10	0/3	1/10	2/0/0/1	1/3	1/3	0/3	3/3	2/3

[Score findings: 0, none; 1, mild (<25%); 2, moderate (25-50%); and 3, severe change (>50%).]

* p – podocytes, pg – parietal glomerular, pc – peritubular capillary, endothelial arteriolar cells

**Figure 2**

Light microscopy in Fabry disease

(A) Renal biopsy of patient 4 with a glomerulus showing hypertrophic glomerular podocytes distended with foamy appearing vacuoles (PAS stain; magnification, x400)

(B) Renal biopsy of patient 3 with a glomerulus showing extensive inclusion bodies of glycolipid in podocytes and parietal cells (arrows; toluidine blue stain; magnification, x 400)

(range 1-4) glomeruli were examined on toluidine blue-stained semi-thin sections.

Renal pathology from light microscopy is described in Table III.

LM showed in all patients varying degrees of hypertrophic glomerular visceral epithelial cells distended with foamy appearing vacuoles (Fig. 2A), corresponding to extracted Gb₃ deposits. There were also vacuoles in parietal glomerular, endothelial cells of peritubular capillary and arterioles in patient 3.

In one biopsy there was mild mesangial widening. In the tubulo-Interstitial compartment, two patients had mild interstitial fibrosis, a chronic inflammatory infiltrate and tubular atrophy (less than 5%). Glomerular sclerosis (segmental or global) was not observed.

Vascular involvement was observed in two patients: arteriolar thickening, hyalinosis and elastic duplication, which led to the initial histological diagnosis of nephroangiosclerosis in one of the cases. The female patient with diabetes mellitus type 2 showed no lesions of diabetic nephropathy.

Semi-thin sections with toluidine blue showed fine but darkly staining granular inclusions (Fig. 2B) in

varying degrees in the cytoplasm of podocytes in all patients. The most prominent location of the inclusions was in podocytes but in two cases (patients 3 and 4) it was present in peritubular capillary, glomerular endothelial and vascular intimal cells.

On frozen sections under polarised light, the glycosphingolipids showed birefringence and autofluorescence (Fig. 3).

Immunofluorescence was negative in all cases (including albumin and Ig G in the diabetic female).

■ Electron microscopy

All the biopsies were analysed by electron microscopy.

In three specimens, podocyte inclusions that varied from granular to concentric lamellated were demonstrated (Fig. 4) and in one biopsy it was also found on peritubular capillaries, parietal glomerular cells and arterial endothelial cells. Inclusions were surrounded by a single unit membrane, indicating their location in lysosomes. Areas of focal fusion of podocyte foot processes were present in three biopsies. No lesions were found in dense membrane of the glomeruli.

Unfortunately in one patient there was no sample for electron microscopy. The diagnosis of Fabry

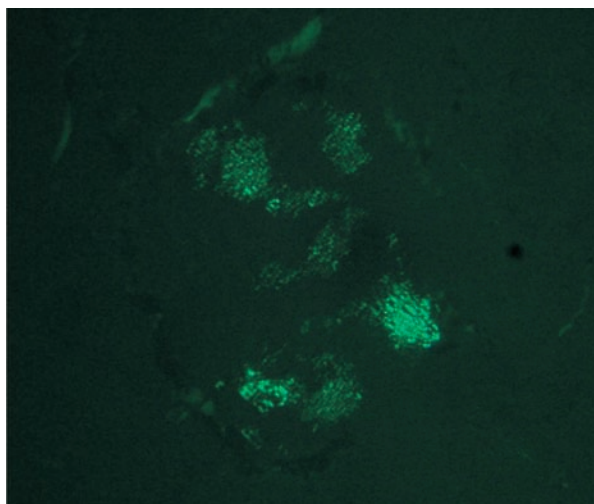


Figure 3

Light microscopy with polarised light (patient 3) showing glycosphingolipids within a glomeruli that are birefringent and exhibit autofluorescence (magnification, x 400)

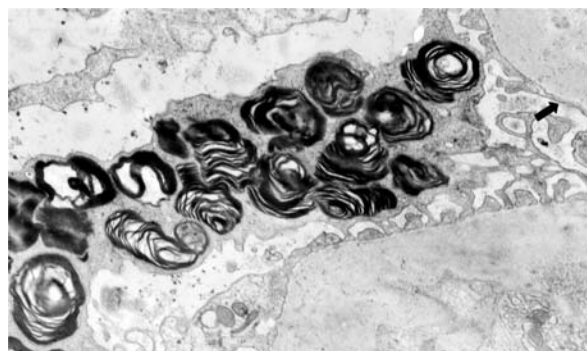


Figure 4

Electron microscopy in renal biopsy of patient 1. Accumulation of storage material, with the appearance of lamellated membrane structures is demonstrated in the secondary lysosomes of podocytes. There is focal foot process effacement (arrow).

disease was made afterwards with identification of *GLA* mutation.

■ DISCUSSION

In this case series of heterozygous females, clinical signs and symptoms varied widely. This phenotypic heterogeneity is thought to be partly due to lyonisation, a process whereby one copy of the X-chromosome is randomly inactivated in all cells of the female embryo¹. Therefore, heterozygous females are essentially a mosaic of normal and mutant cells in varying proportions²¹.

The degree of symptoms depends on the residual enzymatic activity of α -GAL A: females can have anywhere from near-normal levels to no active enzyme¹. Of the 1077 females enrolled in the Fabry Registry, 69.4% had symptoms and signs of FD and twenty percent experienced major cerebrovascular, cardiac, or renal events at a median age of 46 years⁵.

One female of our case series suffered an ischaemic stroke at the age of 38 years and on light microscopy, vascular abnormalities of severe hypertension superimposed on the changes of FD were observed. There is a high prevalence of hypertension, cardiac disease and renal disease in patients who have had a stroke in the context of FD²². Data from the Fabry Registry²² and the Fabry Outcome Survey²³ have shown that the majority of strokes in FD are due to small vessel events. In a large cohort of young Portuguese patients the prevalence of *GLA* missense mutations was 3.8% in patients with cryptogenic stroke, and these mutations were associated with residual α -galactosidase activity levels much higher than those observed in classically affected Fabry patients¹⁴.

Incidental findings of corneal opacity by ophthalmologists can be another sign of FD. Corneal changes (*cornea verticillata*), rarely disturbing visual acuity, are frequently encountered in case series¹ and was detected in one of our patients. Hearing loss has also been reported^{1,15}.

In a small study, subclinical hypothyroidism was found in 36.4% of the patients¹⁶. Hypothyroidism

was detected in one of our four cases. Faggiano *et al.* consider that endocrine work-up should be recommended in all patients suffering from FD¹⁷.

Proteinuria and CKD are important manifestations of Fabry disease⁷. All the female patients had proteinuria and only one had moderate renal function impairment.

According to some authors, proteinuria and/or a reduced glomerular filtration rate may be found in 40% of adult females^{7,18}. Proteinuria was recently shown to be an important risk factor for progression of kidney dysfunction in Fabry disease^{19,20} with a much greater predictive value for men than women²⁰. Deegan *et al.* found that proteinuria was not associated with a more rapid decline in GFR in females¹⁸.

An international effort has been mounted to create a standardised scoring system of the extent and severity of renal involvement, supporting the role of kidney biopsy in the baseline evaluation of Fabry nephropathy. This International Study Group considered that optimal slides for scoring should ideally include >10 glomeruli for light microscopic assessment, and at least 3 glomeruli for semi-thin section scoring⁸. Renal specimens of our study contained a mean glomeruli number of 10 ± 1.6 (range 8-12) present for light microscopy and 2.8 ± 1.3 (range 1-4) on toluidine blue-stained semi-thin sections.

Vacuolisation of podocytes and epithelial cells is a characteristic histological finding⁸. Glomerular parietal epithelial cells are particularly involved in females with severe *GLA* gene mutations¹³ and this was found in patient 3 that had serious extra-renal manifestations of FD.

Fogo *et al.* found that arteriolar hyalinosis was similar in both genders, but females had significantly more arterial hyalinosis which was probably related to their significantly higher age⁸. We detected mild and severe arteriolar hyalinosis, respectively, in two biopsies.

Although mild interstitial fibrosis and tubular atrophy was found in only half of our patients, it should be emphasised that chronic glomerular and interstitial damage develops early in the course of Fabry disease, and the absence of typical clinical signs of CKD does not rule out Fabry nephropathy⁸. Our results are in

agreement with previous series of Fabry patients, showing histological changes before renal function is decreased. Renal biopsy in female patients with FD may therefore be important for establishing the diagnosis and characterisation of renal lesions.

During the study, it became clear to us that histological findings suggestive of Fabry nephropathy (e.g. vacuolisation) may be missed on routine histological sections unless there is a strong clinical suspicion. However, semi-thin sections are best for characterising podocyte Gb3 inclusions⁸.

Cellular inclusions of Gb3 within lysosomes have been described by various names, including zebra bodies and myelin figures, according to different morphologies of their pattern of lamellation. Podocytes and distal tubular epithelial cells have been described as containing the highest concentrations of Gb3²⁴. In some cell types, inclusions appear as small, dark, dense-beaded granules; in others, they appear as larger complex laminated bodies²⁴, as seen in this case series.

Noteworthy is that none of our patients had an history of taking medications known to cause Fabry-like morphologic changes, such as chloroquine, amiodarone, or aminoglycosides²⁵⁻²⁷.

Immunofluorescence was negative in all cases. According to literature, routine immunofluorescence microscopy is usually negative but in glomeruli with advanced lesions, immunoglobulin M, A, and complement components (C3 and C1q) may be detectable in capillary walls and mesangial regions showing a segmental distribution and granular pattern²⁴.

In symptomatic individuals, the diagnosis of FD can be established on the basis of low activity of α -GAL A in plasma, leukocytes or cultured skin fibroblasts²⁸. There is significant overlap in the α -GAL A activity levels of carrier females and the general population; thus, α -GAL A activity may not reliably distinguish the affected (carrier) from unaffected (non-carrier) women. As shown in this series, females had a normal amount of plasma α -GAL A enzyme activity and still carried the defective gene.

For females with normal to low-normal α -GAL A, a genetic test is needed for accurate diagnosis¹⁵.

Mutation subtypes of FD may have impact on disease progression⁹. The mutation Arg112His demonstrated in patients 1 and 2 is predominantly associated with residual enzyme activity and a mild variant phenotype of FD²⁹ which is consistent with our clinical and histological findings.

There are several limitations when analysing our data, especially in rare diseases where the limited number of cases may not be representative of the Fabry female population. The prevalence of CKD and ESRD in the general population is much higher than in Fabry disease and, particularly in patients carrying *GLA* mutations associated with significant residual enzyme activity, it should be noted that the cause of CKD may not always be a consequence of Fabry disease.

The diagnosis of Fabry disease among patients without a positive family history has been a challenge to nephrologists and since Fabry disease is a potentially treatable condition it is imperative to consider it in the differential diagnosis of any patient presenting with proteinuria and/or chronic kidney disease, especially if there is a family history of kidney disease³⁰.

■ CONCLUSION

Clinical signs and symptoms are varied and can be severe among heterozygous females with Fabry disease. Histological renal findings are notorious even in women with little clinical involvement – myelin-like structures were found within lysosomes in many renal cells. Glomerular sclerosis and tubulointerstitial fibrosis are minimal in females with no clinical expression of renal disease.

Fabry disease nephropathy should be considered for diagnosis of any patient presenting with CKD, especially in those with proteinuria and family history of renal disease.

This study should raise the awareness of this rare disease among nephrologists and other specialists that are likely to encounter unrecognised Fabry female patients to improve early diagnosis.

Conflict of interest statement. None declared.

Acknowledgements

The authors gratefully acknowledge the physicians of Fabry disease patients: Dr Carlos Barreto (Setúbal), Dr Jesus Garrido and Dr Joana Vidinha (Viseu), Dr Isabel Pataca (Lisboa) for their contribution to clinical data collection.

References

1. Germain DP. Fabry disease. *Orphanet J Rare Dis* 2010;5:30
2. Meikle PJ, Hopwood JJ, Clague AE, Carey WF. Prevalence of lysosomal storage disorders. *JAMA* 1999;281:249-254
3. MacDermot KD, Holmes A, Miners AH. Anderson-Fabry disease: Clinical manifestations and impact of disease in a cohort of 60 obligate carrier females. *J Med Genet* 2001;38:769-775
4. Anderson-Fabry disease: a nephrology perspective. *J Am Soc Nephrol* 2002;(Suppl 2);13:S125-S153
5. Wilcox WR, Oliveira JP, Hopkin RJ, *et al.* Females with Fabry disease frequently have major organ involvement: lessons from the Fabry Registry. *Mol Genet Metab* 2008;93:112-128
6. Warnock DG, Daina E, Remuzzi G, West M. Enzyme replacement therapy and Fabry nephropathy. *Clin J Am Soc Nephrol* 2010;5:371-378
7. Ortiz A, Oliveira JP, Waldek S, Warnock DG, Cianciaruso B, Wanner C. Nephropathy in males and females with Fabry disease: cross-sectional description of patients before treatment with enzyme replacement therapy. *Nephrol Dial Transplant* 2008;23:1600-1607
8. Fogo AB, Bostad L, Svarstad E, *et al.* Scoring system for renal pathology in Fabry disease: report of the International Study Group of Fabry Nephropathy (ISGFN). *Nephrol Dial Transplant* 2010;25:2168-2177
9. Branton MH, Schiffmann R, Sabnis SG, *et al.* Natural history of Fabry renal disease: Influence of alpha-galactosidase A activity and genetic mutations on clinical course. *Medicine (Baltimore)* 2002; 81:122-138
10. Alroy J, Sabnis S, Kopp JB. Renal pathology in Fabry disease. *J Am Soc Nephrol* 2002;13:S134-S138
11. Najafian B, Svarstad E, Bostad L, *et al.* Progressive podocyte injury and globotriaosylceramide (GL-3) accumulation in young patients with Fabry disease. *Kidney Int* 2011;79: 663-670
12. Gubler MC, Lenoir G, Grunfeld JP, Ulmann A, Droz D, Habib R. Early changes in hemizygous and heterozygous patients with Fabry's disease. *Kidney Int* 1978;13:223-235
13. Valbuena C, Carvalho E, Burstorff M, *et al.* Kidney biopsy findings in heterozygous Fabry disease females with early nephropathy. *Virchow Arch* 2008;453:329-338
14. Baptista MV, Ferreira S, Pinho-e-Melo T, *et al.* Mutations of the GLA gene in young patients with stroke: the POTYSTROKE Study. *Stroke* 2010; 41:431-436
15. Keilmann A, Hajioff D, Ramaswami U. Ear symptoms in children with Fabry disease: data from the Fabry Outcome Survey. *J Inherit Metab Dis* 2009;32:739-744
16. Hauser AC, Gessl A, Lorenz M, Voigtlander T, Fodinger M, Sunder-Plassmann G. High prevalence of subclinical hypothyroidism in patients with Anderson-Fabry disease. *J Inherit Metab Dis* 2005;28:715-722
17. Faggiano A, Pisani A, Milone F, *et al.* Endocrine dysfunction in patients with Fabry disease. *J Clin Endocrinol Metab* 2006; 91:4319-4325.
18. Deegan PB, Baehner AF, Barba Romero MA, *et al.* Natural history of Fabry disease in females in the Fabry Outcome Survey. *J Med Genet* 2006;43:347-352
19. Banikazemi M, Bultas J, Waldek S, *et al.* Agalsidase-beta therapy for advanced Fabry disease: a randomized trial. *Ann Intern Med* 2007;146:77-86
20. Wanner C, Oliveira JP, Ortiz A, *et al.* Prognostic indicators of renal disease progression in adults with Fabry disease: natural history data from the Fabry Registry. *Clin J Am Soc Nephrol* 2010;5:2220-2228
21. Germain DP. Genetics of Fabry disease: diagnostic and therapeutic implications. *Presse Med* 2007;36:S14-S19
22. Sims K, Politei J, Banikazemi M, Lee P. Stroke in Fabry disease frequently occurs before diagnosis and in the absence of other clinical events: natural history data from the Fabry Registry. *Stroke* 2009;40:788-794
23. Fellgiebel A, Muller MJ, Ginsberg L. CNS manifestations of Fabry's disease. *Lancet Neurol* 2006;5:791-795
24. Mehta A, Beck M, Sunder-Plassmann G. Fabry disease: perspectives from 5 years of FOS. *Oxford PharmaGenesis* 2006;Chapter 21.
25. Albay D, Adler SG, Philipose J, Calesdbetta CC, Romansky SG, Cohen AH. Chloroquine-induced lipidosis mimicking Fabry disease. *Mod Pathol* 2005;18:733-738
26. Liu FLW, Cohen RD, Downar E, *et al.* Amiodarone pulmonary toxicity: functional and ultrastructural evaluation. *Thorax* 1986;41:100-105
27. Coulon G, Saint-Hillier Y, Carbillet JP *et al.* Urinary myelin bodies and the nephrotoxicity of aminoglycosides. *Nephrologie* 1984;5:107-114.
28. Chamoles NA, Blanco M, Gaggioli D. Fabry disease: enzymatic diagnosis in dried blood spots on filter paper. *Clin Chim Acta* 2001;308:195-196
29. Eng CM, Niehaus DJ, Enriquez AL, Burgert TS, Ludman MD, Desnick RJ. Fabry disease: twenty-three mutations including sense and antisense CpG alterations and identification of a deletional hot-spot in the alpha-galactosidase A gene. *Hum Mol Genet* 1994;3:1795-1799
30. Fervenza FC, Torra R, Warnock DG. Safety and efficacy of enzyme replacement therapy in the nephropathy of Fabry disease. *Biologics* 2008;2:823-843

Correspondence to:

Dr Ana Natário
 Department of Nephrology, Centro Hospitalar Setúbal
 Rua Camilo Castelo Branco
 2910-446 Setúbal, Portugal
 e-mail: ananatario@hotmail.com