

# Renal pathology in Portuguese HIV-infected patients

Ana Carina Ferreira<sup>1</sup>, Dulce Carvalho<sup>1</sup>, Fernanda Carvalho<sup>1,2</sup>, Maria João Galvão<sup>2</sup>, Fernando Nolasco<sup>1</sup>

<sup>1</sup> Nephrology Department

<sup>2</sup> Renal Pathology Laboratory

Hospital de Curry Cabral, Lisbon, Portugal.

Received for publication: 31/05/2011

Accepted in revised form: 08/11/2011

## ABSTRACT

HIV-infected patients may be affected by a variety of renal disorders. Portugal has a high incidence of HIV2 infection and a low prevalence of HIV-infected patients under dialysis treatment.

The aim of this study was to characterise the type of renal disease in Portuguese HIV-infected patients and to determine if HIV2 infection is associated to renal pathology. Only 60 of the 5158 HIV-infected patients followed in our hospital underwent renal biopsy. Clinical and laboratory data and the type of renal disease were reviewed.

Male gender was predominant (76.7%), as was Caucasian race (78.3%). Mean age was 37.9±10.6 years. The majority had criteria for AIDS, 66% were on combined antiretroviral therapy and 18.3% were on dialysis. The predominant lesions were immune-complex glomerulonephritis (n=19), tubulointerstitial nephropathy (n=12), focal segmental glomerulosclerosis (n=11), followed by HIVAN (n=8). Other patterns (amyloidosis, vasculitis, minimal change lesion) were observed. Only three patients were HIV2 infected, and presented diabetic nephropathy, acute tubular necrosis and tubulointerstitial nephritis. No correlations between clinical findings and renal pathology were found.

In conclusion, renal disease in HIV patients has a broad spectrum, and renal biopsy remains the gold standard for establishing the diagnosis and guide

treatment. Renal disease is not frequent in HIV2-infected patients, and, when present, is probably not directly associated with HIV infection.

### Key-Words:

HIV2; renal biopsy; renal disease.

## INTRODUCTION

Human immunodeficiency virus (HIV) infection was first described in 1981<sup>1</sup>. Since then, its clinical manifestations have changed over the past few decades.

The first association between HIV and the kidney was made in 1984<sup>2</sup>, when a group of investigators described HIV-associated nephropathy (HIVAN) as a focal segmental glomerulosclerosis with collapsing features and severe tubulointerstitial disease. This lesion has been considered the most common histological finding in renal biopsies in HIV1 patients<sup>3-5</sup>, predominantly in blacks<sup>3,5-7</sup>, and has been reported to be the third-leading cause of end-stage renal disease (ESRD) among blacks aged 20 to 64, and the first-leading cause of ESRD in HIV1-infected patients living in the US<sup>6,7</sup>. Recent data suggest that the introduction of combined anti-retroviral therapy (cART) in 1996 changed the spectrum of renal disease, reducing the incidence of HIVAN<sup>8</sup>, and increasing diabetic nephropathy, hypertension and nephrotoxicity.

In Portugal, in December 2009, 37201 notified HIV cases were found: 15685 cases of acquired immunodeficiency syndrome (AIDS), of which 497 were caused by HIV2; 17839 cases of asymptomatic infection and 3677 AIDS-complex related cases<sup>9</sup>. Portugal is the European country with the higher incidence of HIV2 infection, due to historical and socio-economic associations with Africa<sup>10</sup>. Interestingly, HIV2 infection is usually related with reduced incidence of AIDS, better survival and lower viral burden<sup>11</sup>.

Since 1982, the department of infectious diseases in our hospital has followed 5158 HIV patients. To our knowledge, no information on the prevalence of HIV-associated renal disorders has been detailed in Portugal, and only two reports in 2007 studied acute renal injury (AKI) in critically ill HIV-infected patients admitted to an Intensive Care Unit<sup>12,13</sup>. AKI was associated with increased mortality.

This retrospective study aims to characterise the type of renal disease found in Portuguese HIV-infected patients and to verify whether HIV2 infection is associated to renal disorders. Clinical and laboratory records at the date of biopsy were reviewed.

## ■ PATIENTS AND METHODS

This was a retrospective review of all biopsies from HIV-infected patients received by our laboratory, from January 1989 to January 2009. All examined slides contained at least six glomeruli per section. Tissues for optical microscopy were stained with haematoxylin-eosin, periodic acid Schiff, Masson's trichrome, methenamine silver and Congo red.

Focal segmental glomerulosclerosis (FSGS) was diagnosed by glomerular scarring and fusion/effacement of foot processes, without IgA deposits. At least one glomerulus with segmental or global glomerular capillary loop collapse with wrinkling of the basement membrane, and marked proliferation and hypertrophy of overlying podocytes, associated to noticeable tubulointerstitial disease was required for HIVAN diagnosis. Membranous nephropathy was diagnosed if there were increased thickness of capillary walls, spikes and subepithelial deposits. Membranoproliferative glomerulonephritis (MPGN) was defined when mesangial cell proliferation, double

contours and subendothelial deposits were presented. Proliferative glomerulonephritis was characterised by the presence of extensive endocapillary proliferation, normal capillary walls and positive immunofluorescence (IMF). Mesangial proliferation with IgA deposits was required for IgA nephropathy identification. Amyloidosis was detected by Congo red birefringence. Tubulointerstitial disease was diagnosed by interstitial oedema, fibrosis, and tubular damage, with no glomeruli alterations.

The degrees of interstitial infiltrate, interstitial fibrosis and tubular atrophy was considerate mild if involved cortical was <30%, moderate if between 30 to 60% and severe if >60%. Microcystic dilatation of renal tubules, acute tubular necrosis and the vessels status were noted.

IMF was performed in frozen sections, using labelled human immunoglobulin (IgA, IgG, IgM), C3, C4, C1q and fibrinogen. When no frozen fragment was available, indirect immunoperoxidase using formalin-fixed paraffin embedded section was performed. The deposits by IMF were graded from 0 to 3+ and the location described as mesangial, subepithelial or subendothelial. Deposits in tubular basement membranes, peritubular capillaries and interstitium were checked. When required, electron microscopy was performed.

Clinical and laboratory data at the time of biopsy were obtained: age, gender, race, hepatitis B virus (HBV), hepatitis C virus (HCV), and others co-infections, intravenous drug use, cART, dialysis requirement, fasting plasma glucose, serum creatinine (Scr), 24-hour proteinuria, haematuria, ANA, anti-DNA, ANCA, cryoglobulins, C3, C4, CD4 lymphocyte count and HIV RNA level. AIDS was defined by CD4 T cells count below 200 per  $\mu\text{L}$  of blood or presence of AIDS-defining illnesses (cachexia, cryptococcal meningitis, tuberculosis, Kaposi's sarcoma, neurological impairment, candidiasis of the oesophagus, invasive cervical cancer, life-threatening pneumonia).

## ■ Statistical analysis

Independent variables were compared using the Mann-Whitney and the chi-squared tests. Univariate analysis was made using the Spearman test. All tests were performed using the SPSS system 18.0.

## RESULTS

From January 1989 to January 2009, 4532 biopsies were performed in our department, 57 in HIV1 and 3 in HIV2-infected patients. The baseline clinical characteristics of HIV patients are summarised in Tables I and II. Male gender (76.7%) and Caucasian race (78.3%) were predominant. Mean age was  $37.9 \pm 10.6$  years. Co-infections and intravenous drug use were present in 50% and 53.3%. The majority had AIDS criteria, and 66% were on cART. Only 18.3% were on dialysis.

Ten different histological findings were recognised. The histological features are summarised in Table III. The predominant lesion was immune-complex glomerulonephritis (ICGN) present in 19 patients, followed by tubulointerstitial nephropathy ( $n=12$ ), FSGS ( $n=11$ ) and HIVAN ( $n=8$ ).

### 1) Immune-complex glomerulonephritis (ICGN)

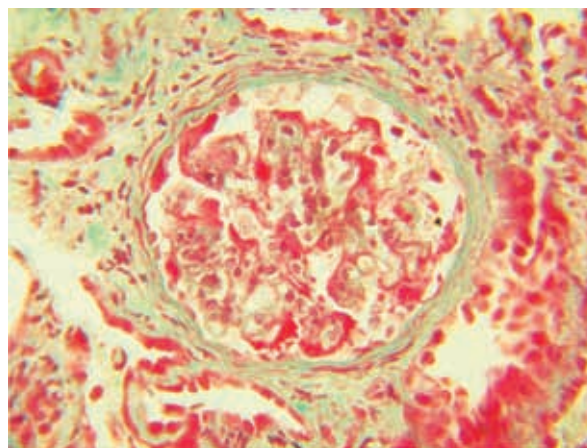
This was the most common histological finding in our population, ascertained in 19 patients (32%): nine patients with MPGN; eight with proliferative glomerulonephritis; one with IgA nephropathy and one with membranous nephropathy. All patients were HIV1 positive.

#### 1.a) MPGN type I

Renal biopsy was performed due to nephrotic syndrome ( $n=5$  patients), proteinuria ( $n=3$ ) and AKI ( $n=1$ ). Mean age was  $35.3 \pm 7$  years, 80% had AIDS and 33.3% were on cART. Patients were Caucasian and co-infected: six had HCV ( $p=0.004$ ), two had HCV and HBV and one had Kaposi sarcoma. All patients with hepatitis were intravenous drug users. No patients had clinical or serological signs for lupus. Mean Scr was low ( $1.9 \pm 1.1$  mg/dl), and mean proteinuria was high ( $5.6 \pm 6.4$  g). Haematuria was present in seven (78%) patients. Histology revealed mild interstitial fibrosis ( $p<0.005$ ) and there were no microcystic tubules. IMF was positive in all patients.

#### 1.b) Proliferative glomerulonephritis

Renal biopsy was performed due to nephrotic syndrome ( $n=5$  patients), proteinuria ( $n=2$ ) and AKI ( $n=1$ ). Caucasian race was predominant. Half of the



**Figure 1**

Proliferative glomerulonephritis. Hyperplastic podocytes with red intracytoplasmic reabsorption droplets (Masson trichrome stain x250).

patients were HCV co-infected and intravenous drug users, one patient was only intravenous drug user, without hepatitis. Mean Scr was low ( $1.7 \pm 1.3$  mg/dl), mean proteinuria was high ( $6.4 \pm 6.3$ g), and all had haematuria ( $p=0.01$ ). No patients had clinical or serological signs for lupus. Renal histology was characterised by two different findings. In four (50%) patients, crescentic glomerulonephritis ( $p<0.001$ ), accompanied by variable degrees of interstitial infiltrate, fibrosis, tubular atrophy, and positive IMF for C3, IgM and IgA was observed. In another four patients, diffuse proliferative endocapillary exudative glomerulonephritis (Fig. 1), with hypercellularity of all glomeruli, no significant interstitial infiltration or tubular atrophy, and positive IMF for C3 and IgG (3/4) and for C3, C1q and IgM (1/4) were found.

#### 1.c) IgA nephropathy

This biopsy was obtained from a 59-year-old white male. Glomeruli had mesangial proliferation with no crescents; interstitial alterations were moderate and there was no dilatation of tubules. IMF staining for IgA was predominant.

#### 1.d) Membranous glomerulopathy state II

This biopsy was obtained from a 40-year-old white male, intravenous drug user and HBV co-infected.

Renal biopsy showed a mild interstitial infiltrate, moderate fibrosis and tubular atrophy, with no dilatation of tubules. IMF was not available.

## ■ 2) Tubulointerstitial nephropathy

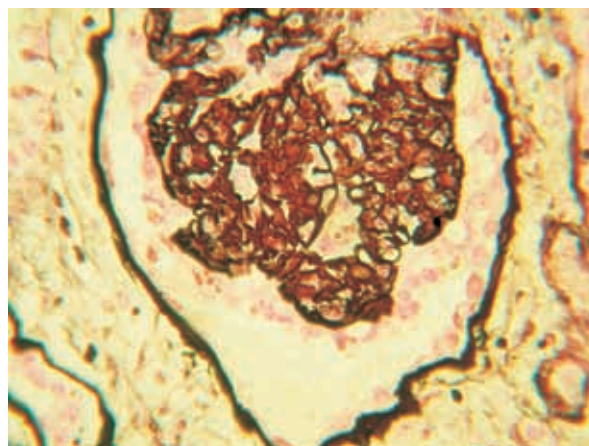
A predominant interstitial pathology was present in 12 patients: three with acute tubulointerstitial nephropathy biopsied due to AKI, and nine with features of chronicity who required renal biopsy due to AKI (n=4), rapidly progressive renal insufficiency (n=2), and proteinuria (n=3). In 88.9% cART was used. Mean Scr was  $3.9 \pm 2.7$  mg/dl. HIV2 infection was present in one patient with chronic tubulointerstitial nephropathy on cART. All patients had normal glomeruli and marked interstitial nephritis. Crystals were found in one patient that used indinavir. Chronicity was correlated with age ( $p=0.01$ ), interstitial infiltrate ( $p=0.006$ ), interstitial fibrosis ( $p=0.002$ ) and tubular atrophy ( $p=0.005$ ).

## ■ 3) FSGS

This lesion was present in 11 HIV1-infected patients, and all biopsies were performed due to nephrotic syndrome (mean proteinuria  $6.2 \pm 4.9$ g). Mean age was  $36.2 \pm 11.7$  years and Caucasian race was predominant (81.8%). HBV co-infection was present in one patient and HCV in five (four of these also intravenous drug users). Mean CD4 count was  $196 \pm 132.3$  cells/mm<sup>3</sup>, mean RNA levels were  $222695.2 \pm 427068.5$  copies/ml. Only one patient had microcystic dilatation of tubules, without collapsing pattern, mild interstitial fibrosis, no cellular infiltration and no staining on IMF. The others presented without dilatation of tubules and, overall, with mild degrees of infiltrate, fibrosis and tubular atrophy. IMF was positive with segmental deposits of C3 and IgM in 5/8 patients.

## ■ 4) HIVAN

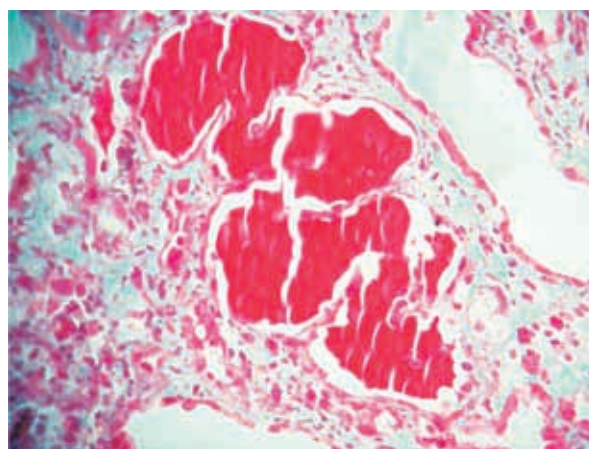
This pattern (Fig. 2) was found in eight HIV1-infected patients, and biopsies were performed due to nephrotic syndrome (n=2 patients), proteinuria (n=1), rapidly progressive renal insufficiency (n=4), and haematoproteinuria (n=1). Black race was predominant (75%,  $p=0.02$ ), all patients had AIDS and



**Figure 2**

Collapsing capillaries with hyperplastic podocytes, and protein resorption droplets (Jones methenamine silver x400).

only three (37.5%) were on cART. Mean age was  $35.9 \pm 7.5$  years. HBV co-infection was present in one patient and HCV in two (these also intravenous drug users). All had low CD4 count ( $35 \pm 9$  cells/mm<sup>3</sup>), high RNA levels ( $530902 \pm 2508$  copies/ml), heavy proteinuria ( $5.6 \pm 6.1$ g), advanced renal failure (Scr  $4.8 \pm 2.4$  mg/dl) and 50% were on haemodialysis ( $p=0.01$ ). Renal histology was characterised by microcystic distortion of the tubules ( $p<0.001$ ) (Fig. 3), severe



**Figure 3**

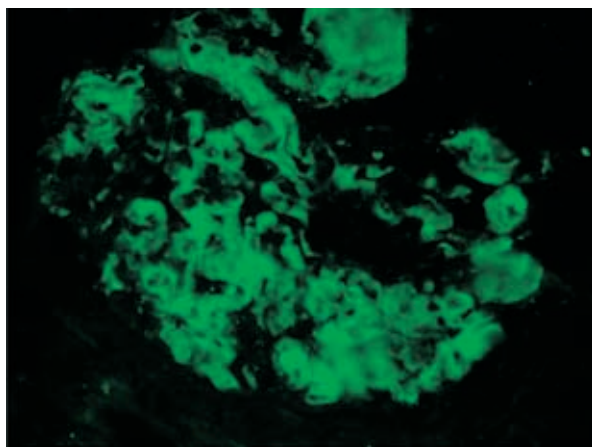
Microcystic dilatation of the tubules, that are filled with proteinaceous casts (PAS x250)



lymphocyte infiltration ( $p=0.04$ ), fibrosis ( $p<0.001$ ) and tubular atrophy ( $p=0.004$ ). On IMF, four patients had staining for C<sub>3</sub>, three had C<sub>3</sub> and IgM and one had C<sub>3</sub> and C1q.

### 5) AA Amyloidosis

This was found in three HIV1-infected Caucasian patients, and all biopsies were performed due to nephrotic syndrome [mean proteinuria  $9.3\pm 4.1$ g ( $p=0.04$ )]. One patient had Crohn's disease, one had pulmonary tuberculosis and one was intravenous drug user. Glomeruli were sclerosed and had mesangial nodules. Tubular atrophy was severe ( $p=0.03$ ), fibrosis and interstitial infiltrates were moderate. Scarce deposits of C<sub>3</sub>, C1q, IgG and IgM were found in two patients (Fig. 4).



**Figure 4**  
AA Amyloidosis (immunofluorescence stain x400).

### 6) Other renal diseases

- Minimal change lesion: one HIV1-infected female patient with syphilis.
- Chronic glomerulonephritis: one HIV1-infected patient.
- Microscopic polyarteritis: two HIV1-infected males, pANCA+.
- Acute tubular necrosis (ATN): one HIV1-infected and one HIV2-infected patient.
- Diabetic nephropathy: one HIV2-infected patient.

## DISCUSSION

About 5 to 10% of HIV1-infected patients will develop kidney dysfunction during the course of HIV disease<sup>7</sup>. Introduction of cART has improved survival, with consequent increased prevalence of the infection. In addition, as this population is aging, other problems such as diabetes or hypertension may be responsible for kidney disease.

In 2009, the Portuguese Society of Nephrology registered 10,217 patients under dialysis treatment and only 102 (0.998%) were HIV infected<sup>14</sup>.

We studied 60 biopsied HIV patients and a variety of histological findings were identified: the predominant lesion was ICGN ( $n=19$  patients), followed by tubulointerstitial nephritis ( $n=12$ ), FSGS ( $n=11$ ) and HIVAN ( $n=8$ ).

This study raises several points. Renal lesion affects predominantly men. In fact, according to our infectious diseases department, HIV patients are mainly males.

Although Portugal is the European country with a high number of HIV2-infected patients<sup>10</sup>, only three in sixty patients were HIV2 infected, and all had probable virus unrelated lesions: chronic tubulointerstitial

**Table 1**

Clinical characteristics of HIV1-infected patients

	Patients
HIV1 (n)	57
Gender	
Male	77.2% (44)
Female	22.8% (13)
Caucasian race (%)	77.1% (44)
Black race (%)	22.8% (13)
Age (yr)	37.6±10
Hepatitis B virus infection (%)	14% (8)
Hepatitis C virus infection (%)	47.4% (27)
Intravenous drug use (%)	61.5% (32/52)
Acquired immunodeficiency syndrome (%)	89.2% (33/37)
Highly active antiretroviral therapy (%)	70.7% (29/41)
Renal replacement therapy (%)	17.5% (10)
CD4 lymphocyte count (cells/mm)	367.2±184.2
Plasma HIV RNA level (copies/ml)	147086.4±274399.8
Serum creatinine (mg/dl)	3.1±2.6
Proteinuria (g)	5.3±6.1
Haematuria (%)	57.4% (27/47)

**Table II**

Clinical characteristics of HIV2-infected patients

	Patients
HIV2 (n)	3
Gender	
Male	66.7% (2)
Female	33.3% (1)
Caucasian race (%)	100%
Age (yr)	45±19.9
Hepatitis B virus infection (%)	0%
Hepatitis C virus infection (%)	0%
Intravenous drug use (%)	100%
Acquired immunodeficiency syndrome (%)	0%
Highly active antiretroviral therapy (%)	33.3% (1)
Renal replacement therapy (%)	33.3% (1)
CD4 lymphocyte count (cells/mm)	499.4±78
Plasma HIV RNA level (copies/ml)	NA
Serum creatinine (mg/dl)	3.7±1.1
Proteinuria (g)	1±1.7
Haematuria (%)	33.3% (1)

NA: non available

nephropathy, diabetic nephropathy and acute tubular necrosis. HIV2 has an apparent lack of nephrotoxicity compared to HIV1, and perhaps it is related to its virulence. HIV2 was identified in 1986, and almost 95% of the infected patients are referred to be long-term non-progressors: HIV2-infected patients have slower progression of the disease, and, usually, have more time without opportunistic disorders and/or with high CD4 count. HIV2 transmission pathways are the same for HIV1, but the probability of the transmission is lower, for instance, vertical infection is very rare in this virus.

Pathogenesis of CKD in HIV1 infection seems to be due to an association of at least three factors: viral infection (that cause epithelial tubular and epithelial glomerular cells deregulation by direct infection, and by indirect toxicity due to HIV1 genes *nef*, and *Vpr*), immune activation (that is produced by viral replication and its independent on viral genes) and genetic predisposition of the patient to renal disease. Pathogenesis of CKD in HIV2 infection is not studied. HIV2 can cause immunodeficiency but rarely causes kidney disease. Although HIV2 has a more benign natural history, the virus has a high number of co-receptors for entry in CD4 T cells, and, likewise, it is probable that the mode of HIV2 entry into renal cells differs from HIV1. Nevertheless, HIV2-infected patients present capacity for IL2 production and high lymphocyte turnover, which relates

to its benign immune pathogenesis. Therefore, HIVAN is considered to be caused by HIV1 infection and rare cases have been described associated with HIV2 infection.

Contrary to US and some European studies, in our study HIVAN was not the predominant lesion<sup>5</sup>, but similarly, it affected preferentially black patients, with low CD4 counts, high RNA levels, severe interstitial damage and worse renal function<sup>3-7</sup>. Comparing the clinical characteristics of HIVAN and FSGS, no differences were found concerning age and gender. Black race was predominant in HIVAN, as opposed to Caucasian race in FSGS; HCV infection was common in FSGS, as the use of cART. Scr and dialysis requirement were higher in HIVAN.

Nowadays, it is a point of discussion whether HIVAN and FSGS are identical or different disorders. According to the Columbia classification, collapsing glomerulopathy is considered to be a variant of FSGS. However Barisoni *et al.* proposed that it should be a distinct podocytopathy<sup>15</sup>. This entity is characterised by hyperplastic and hypertrophic podocytes, contrary to FSGS where podocytopaenia is the rule. The same author, in 1999, evidenced the abnormal maturation and differentiation of podocytes in both idiopathic collapsing glomerulopathy and HIVAN<sup>16</sup>. From then, the direct effect of HIV1 on those cells has been studied, but the pathogenesis of HIVAN still remains to be elucidated. It is difficult to detect HIV1 antigens in tissue<sup>17</sup>; HIV1 genes expression in renal cell is a prerequisite for the development of HIVAN<sup>18</sup> and it has been shown that *nef* is able to induce molecular alterations that transform the podocyte phenotype<sup>19</sup>, with loss of cell cycle quiescence and differentiation anomalies in glomeruli. Protein *nef* evolved to help HIV1 escape host immunity by downregulating key cell surface receptors on lymphocytes, and major histocompatibility complex class I. The route by which HIV1 enters renal cells is not clear, as tubular cells do not express the classic receptors for HIV1; nevertheless, Hatsukari *et al.* have demonstrated the DEC-205 receptors expression, which mediates internalisation of the virus<sup>20</sup>. Still, the origin of the highly proliferating glomerular cells in HIVAN is also not understood: Bariety *et al.* showed that parietal epithelial cells do exist along a normal human Bowman's capsule and do have the ability to divide<sup>22</sup>. Others identified a population of renal progenitors CD133<sup>+</sup>CD24<sup>+</sup>, exhibiting

**Table III**

Clinical characteristics of patients according to histological findings

	MPGN (n=9)	PGN (n=8)	TI nephrop. (n=12)	FSGS (n=11)	HIVAN (n=8)	AA (n=3)
Age (yr)	35.3±7	34.2±8.2	41.7±11.5	36.2±11.7	35.9±7.5	37±7.2
Male gender (%)	88.9% (8)	87.5% (7)	58.3% (7)	81.8% (9)	75% (6)	33.3% (1)
Black race (%)	0%	0%	16.7% (2)	18.2% (2)	75% (6)*	0%
HBV infection (%)	22% (2)	0%	25% (3)	9.1% (1)	12.5% (1)	0%
HCV infection (%)	88.9% (8)**	50% (4)	50% (6)	45.5% (5)	25% (2)	33.3% (1)
Intravenous drug use (%)	88.9% (8)*	62.5% (5)	58.3% (7)	55.6% (5/9)	42.9% (3/7)	50% (1/2)
AIDS (%)	80% (4/5)	100% (3/3)	88.9% (8/9)	75% (6/8)	100% (9)	66.7% (2)
HAART (%)	33.3% (2/6)	60% (3/5)	88.9% (8/9)	63.6% (7)	37.5% (3)	33.3% (1)
Renal replacement therapy (%)	0%	0%	25% (3)	0%	50% (4)*	33.3% (1)
CD4 count (cells/mm)	196.3±91.5	300±12.7	152±177.4	196±132.3	35±9	50±33.2
Viral load (RNA copies/ml)	278078.7 ±326711	41117± 58156	15762.5 ±16484.1	222695.2 ±427068.5	530902 ±25008	30000 ±3765
Serum creatinine (mg/dl)	1.9±1.1	1.7±1.3 -*	3.9±3	1.5±0.8-**	4.8±2.4*	3.7±2.4
Proteinuria (g)	5.6±6.4	6.4±6.3	1±1 -**	6.2±4.9	5.6±6.1	9.3±4.1*
Haematuria (%)	70% (7)	100%*	41.7% (5)	18.2% (2)-*	44.4% (4)	0%
Microcystic distortion (yes)2	0%	25% (2)	16.7% (2)	9% (1)	75% (6)**	0%
Tubular atrophy1	Mild: 7** Moderate: 2	Mild: 5 Moderate: 2 Severe: 1	Mild: 2 Moderate: 3 Severe: 7*	Mild: 8 Moderate: 1 Severe: 2	Moderate: 2 Severe: 6**	Severe: 3*
Lymphocyte infiltration1	Mild: 5** Moderate: 3 Severe: 1	Mild: 4 Moderate: 1 Severe: 3	Moderate: 7 Severe: 5**	Mild: 9 Moderate: 1 Severe: 1	Mild: 1 Moderate: 3 Severe: 4*	Moderate: 3
Interstitial fibrosis1	Mild: 6* Moderate: 3	Mild: 4 Moderate: 2 Severe: 2	Mild: 1 Moderate: 5 Severe: 6*	Mild: 7 Moderate: 3 Severe: 1	Moderate: 1 Severe: 7**	Moderate: 3

\*p&lt;0.05 \*\*p&lt;0.005

HIVAN: HIV-associated nephropathy; FSGS: Focal segmental glomerulosclerosis; MPGN: Membranoproliferative glomerulonephritis; PGN: Proliferative glomerulonephritis; AA: AA amyloidosis; TI nephrop.: tubulointerstitial nephropathy

1 The degree of active interstitial infiltrate and interstitial fibrosis was estimated as a percentage of the cortical involved, considered mild if &lt;30%, moderate if between 30 to 60% and severe if &gt;60%. The tubular atrophy is estimated in the same manner.

2 The presence of microcystic dilatation of renal tubules were analysed; the numbers refer to number of patients with (yes) microcystic dilatation

self-renewal potential that might be responsible for exuberant glomerular injury repair<sup>23</sup>. It is still unknown why some injuries trigger podocyte damage with detachment from the basement membrane, while others stimulate their proliferation<sup>24</sup>. Therefore, it may be possible that other factors such as genetic trail, mechanical stress, or additional stimuli define the type of glomerular lesion. Zhong *et al.* demonstrated that susceptible genetic background is important to the development of HIVAN in transgenic mice<sup>25</sup>. Recently, MYH9 or missense mutations (S342G, I384M) in the neighbouring APOL1 gene have been considered to be responsible for the genetic susceptibility of African-Americans to HIVAN<sup>26</sup>. In addition, inflammatory mediators, such as viral proteins, cause Notch activation by TGFβ, which results in podocyte proliferation. The Notch receptor

family includes four members, is anchored in the cell membrane, and is involved in short-range cell-cell communication, cell-fate decision, patterning and cell polarity. The Notch pathway is indispensable for glomerular development, and ectopic Notch activation in developing podocytes causes glomerulosclerosis in developing murine kidneys and opposes terminal differentiation of podocytes<sup>27</sup>. The increased expression of Notch target protein in glomeruli of transgenic mice and the upregulation of cleaved Notch1 and Notch4 in human biopsies have been observed in HIVAN<sup>28</sup>. A recent study raised the hypothesis that in HIVAN the phenotype of tubular epithelial cells may change to what we call epithelial-mesenchymal transition (EMT)<sup>21</sup>. EMT contributes to an aggressive tubulointerstitial lesion with formation of extensive fibrosis.

In our population, as in most European countries, the most common histological pattern was ICGN, which was associated with Caucasian race, hepatitis virus co-infection and intravenous drug use, namely heroin. In fact, these two last agents are well-known causes of glomerular damage in non-HIV patients<sup>39-31</sup>. ICGN pathogenesis is unknown, and it seems that it is not related to HIV1 infection itself, but instead related to an autoimmune event: immune abnormal response to viral proteins, and/or immune abnormal response to secondary superinfections, and/or presence of co-infections (mainly HBV and HCV). So, it is not the HIV1 infection itself, instead the immune response to the virus that gives rise to these lesions. Co-infections appear as confounding factors for renal disease in these disorders. Although all histological patterns were associated with low CD4 count and high RNA levels, these associations were more obvious in HIVAN pattern. The interstitial area was notably different from HIVAN, as no microcystic dilatation was seen and only mild damage was evident. Gerntholtz *et al.* have described a pattern of mesangial and paramesangial proliferation, denominated “ball-in-cup”<sup>32</sup>. Swanepoel *et al.* also described this lesion as a variant of post-infectious or membranous glomerulonephritis, and described other variants, the “central sclerosis” variant and “foetal glomeruli”<sup>33</sup>, that we did not find. Associations between HIV infection and IgA nephropathy in Caucasian males have been made. Indeed, immune complexes containing IgA are frequently seen in these individuals<sup>4</sup> and polyclonal increase in serum IgA is a common feature of AIDS. We found only one case.

Tubulointerstitial nephropathy was associated with cART, raising the question of nephrotoxicity. In accordance, this lesion is usually induced by medication. Nevertheless, we cannot exclude that HIV can produce an interstitial disease on its own.

Some unexpected patterns were found. Secondary amyloidosis is an uncommon cause for renal disease in HIV patients. Chronic inflammation due to Crohn’s disease and tuberculosis justified this finding in two patients. In the third, chronic soft tissue infection related to intravenous drug use; *skin popping*<sup>34</sup>, was probably the cause. Of note, HIV1 disease induces a permanent immune activation and elevation of inflammatory mediators. In this scenario, AA amyloidosis might develop. Minimal change lesion, a T-cell

mediated disease<sup>35</sup>, and microscopic polyarteritis were also unexpected histological findings. The role of the virus in these non-HIV-related nephropathies remains unclear.

ATN is the most common cause of intrinsic AKI in HIV patients. This pattern was only diagnosed in two patients, as biopsies are only performed if a suspected ATN remains after four weeks.

The apparent low number of kidney biopsies may be explained by the fact that, in our hospital, the majority of acute renal dysfunction cases seen in HIV are linked to ATN. Arendse *et al.* also highlight the high frequency of ATN and its importance in survival on AKI in HIV-positive patients<sup>36</sup>. In addition to suspected ATN, some patients, when referred to our department, already have reduced-sized kidneys, contraindicating kidney biopsy. However, renal failure may not be frequent in Lisbon/Portugal, as only 0.99% of dialysis patients are HIV infected. Obviously, one might argue that the majority of patients died before initiating dialysis. According to Instituto Ricardo Jorge, in 2009, 1273/15020 (48.4%) died, 41.2% from opportunistic infection including tuberculosis, not justifying the reduced number of HIV patients in dialysis. Unfortunately, we have no information regarding the outcome in the majority of the patients, and, in the majority, the length of HIV infection was not recorded. It would be interesting to discuss if time alters nephropathy characteristics.

In conclusion, in our population the three major histological patterns found were ICGN, tubulointerstitial nephritis and FSGS. HIVAN was the fourth lesion and related to black race. No correlations between data and pattern of renal disease were seen; therefore it is not possible to predict the renal disease based on clinical criteria. Renal biopsy remains the gold standard for establishing the diagnosis. It appears that HIV2-infected patients have an unexplained low incidence of renal disorders. It is highly probable that a variety of factors other than virus related may be necessary for kidney damage and/or development of kidney failure.

**Conflict of interest statement.** None declared.

The results of this study were presented in abstract form at the WCN May 2009. Milan. Italy.



## References

1. CDC. Pneumocystis pneumonia – Los Angeles. *MMWR Morb Mortal Wkly Rep* 1981;30:250-252
2. Pardo V, Aldana M, Colton RM, *et al.* Glomerular lesions in the acquired immunodeficiency syndrome. *Ann Intern Med* 1984;101:429-434
3. Weiner NJ, Goodman JW, Kimmel PL. The HIV associated renal diseases: current insight into pathogenesis and treatment. *Kidney Int* 2003;63:1618-1631
4. Winston JA, Bruggeman LA, Ross MD, *et al.* Nephropathy and establishment of a renal reservoir of HIV type 1 during primary infection. *N Eng J Med* 2001;344:1979-1984
5. Szczec LA, Gupta SK, Habash R, *et al.* The clinical epidemiology and course of the spectrum of renal diseases associated with HIV infection. *Kidney Int* 2004;66:1145-1152
6. Shah SN, He JC, Klotman P. Update on HIV-associated nephropathy *Curr Opin Nephrol Hypertens* 2006;15:450-455
7. Ross MJ, Klotman PE. Recent progress in HIV-associated nephropathy. *J Am Soc Nephrol* 2002;13:2997-3004
8. Schwartz EJ, Szczec LA, Ross MJ, Klotman ME, Winston JA, Klotman PE. Highly active antiretroviral therapy and the epidemic of HIV+ end-stage renal disease. *J Am Soc Nephrol* 2005;16:2412-2420
9. [http://www.aidsportugal.com/recursos/sida122007\\_fev2009.pdf](http://www.aidsportugal.com/recursos/sida122007_fev2009.pdf)
10. Soriano V, Gomes P, Heneine, *et al.* Human immunodeficiency virus type 2 (HIV2) in Portugal: clinical spectrum, circulating subtypes, virus isolation, and plasma viral load. *J Med Virol* 2000;61:111-116
11. Marlink R, Kanki P, Thior I, *et al.* Reduced rate of disease development after HIV-2 infection as compared to HIV-1. *Science* 1994;265(5178):1587-1590
12. Lopes JA, Fernandes J, Jorge S, Neves J, Antunes F, Martins Prata M. Acute renal failure in critically ill HIV infected patients. *Crit Care* 2007;11:404(Letter)
13. Lopes JA, Fernandes J, Jorge S, Neves J, Antunes F, Martins Prata M. An assessment of the RIFLE criteria for acute renal failure in critically ill HIV infected patients. *Crit Care* 2007;11:401(Letter)
14. Annual Registry Report. Portuguese Society of Nephrology. 2009. [www.spnefro.pt](http://www.spnefro.pt)
15. Barisoni L, Schnaper W, Kopp J. A. proposed taxonomy for the podocytopathies: a reassessment of the primary nephrotic diseases. *Clin J Am Nephrol* 2007;2:529-542
16. Barisoni L, Kriz W, Mundel P, D'Agati V. The dysregulated podocyte phenotype: a novel concept in the pathogenesis of collapsing idiopathic focal segmental glomerulosclerosis and HIV- associated nephropathy. *J Am Soc Nephrol* 1999;10:51-61
17. Nodasdy T, Hanson-Painton O, Davis LD, *et al.* Conditions affecting the immunohistochemical detection of HIV in fixed and embedded renal and nonrenal tissues. *Mod Pathol* 1992;5:283-291
18. Bruggeman LA, Dikman S, Meng C, Quaggin SE, Coffman TM, Klotman PE. Nephropathy in human immunodeficiency virus-1 transgenic mice is due to renal transgene expression. *J Clin Invest* 1997;100:84-92
19. Husain M, D'Agati VD, He JC, Klotman ME, Klotman PE. HIV-1 Nef induces dedifferentiation of podocytes in vivo: a characteristic feature of HIVAN. *AIDS* 2005;19:1975-1980
20. Hatsukari I, Singh P, Hitosugi N, *et al.* DEC-205-mediated internalization of HIV-1 results in the establishment of silent infection in renal tubular cells. *J Am Soc Nephrol* 2007;18:780-787
21. Yadav A, Vallabu S, Kumar D, *et al.* HIVAN phenotype: consequence of epithelial mesenchymal transdifferentiation. *Am J Physiol Renal Physiol* 2010;298:F734-F744
22. Bariety J, Mandet C, Hill GS, Bruneval P. Parietal podocytes in normal human glomeruli. *J Am Soc Nephrol* 2006;17:2770-2780
23. Smeets B, Angelotti ML, Rizzo P, *et al.* Renal progenitor cells contribute to hyperplastic lesions of podocytopathies and crescentic glomerulonephritis. *J Am Soc Nephrol* 2009;20:2593-2603
24. Kretzler M. Role of podocytes in focal sclerosis: defining the point of no return. *J Am Soc Nephrol* 2005;16:2830-2832
25. Zhong J, Zuo Y, Ma J, *et al.* Expression of HIV-1 genes in podocytes alone can lead to the full spectrum of HIV-1-associated nephropathy. *Kidney Int* 2005;68:1048-1060
26. Tzur S, Rosset S, Shemer R, *et al.* Missense mutations in the APO1 gene are highly associated with end stage kidney disease risk previously attributed to the MYH9 gene. *Hum Genet* 2010;128:345-350
27. Mertens PR, Raffetseder U, Rauen T. Notch receptors: a new target in glomerular diseases. *Nephrol Dial Transplant* 2008;23:2743-2745
28. Sharma M, Callen S, Zhang D, *et al.* Activation of Notch signaling pathway in HIV-associated nephropathy *AIDS* 2010;24:2161-2170
29. Barsoum RS. Hepatitis C virus: from entry to renal injury – facts and potentials. *Nephrol Dial Transplant* 2007;22:1840-1848
30. Olsen SK, Brown RS Jr. Hepatitis B treatment: lessons for the nephrologist. *Kidney Int* 2006;70:1897-1904
31. Dubrow A, Mittman N, Ghali V, Flamenbaum W. The changing spectrum of heroin-associated nephropathy. *Am J Kidney Dis* 1985;5:36-41
32. Gemtholtz TE, Goetsch SJ, Katz I. HIV-related nephropathy: a South African perspective. *Kidney Int* 2006;69:1885-1891
33. Swanepoel CR, Okpechi IG. HIV and renal disease in Africa: the journey so far and future directions. *Port J Nephrol Hypert* 2011;25:11-15
34. Connolly JO, Gillmore JD, Lachmann HJ, Davenport A, Hawkins PN, Woolfson RG. Renal amyloidosis in intravenous drug users *QJM* 2006;99:737-742
35. Cunard R, Kelly CJ. T cells and minimal change disease. *J Am Soc Nephrol* 2002;13:1409-1411
36. Arendse C, Okpechi I, Swanepoel C. Acute dialysis in HIV-positive patients in Cape Town, South Africa. *Nephrology (Carlton)* 2011;16:39-44

## Correspondence to:

Dr Ana Carina Ferreira  
 Department of Nephrology  
 Hospital de Curry Cabral  
 Rua da Beneficência nº8, 1069-639 Lisboa  
 karinadacostafer@hotmail.com