

## Idiopathic pneumatosis intestinalis in a haemodialysis patient

Juan Martin Navarro<sup>1</sup>, Maria José Gutierrez Sanchez<sup>1</sup>, Evangelina Merida Herrero<sup>1</sup>, Elías Rodríguez Cuellar<sup>2</sup>, Javier Barrientos Sabugo<sup>2</sup>, Eduardo Garcia de la Piedra Puentes<sup>3</sup>, José Manuel Domínguez Espejo<sup>4</sup>

<sup>1</sup>Nephrology Service

<sup>2</sup>General and Digestive Surgery Service

<sup>3</sup>Anaesthesia Service

<sup>4</sup>Radiology Service

Hospital del Tajo. Aranjuez, Madrid, Spain.

Received for publication: 24/09/2009

Accepted in revised form: 08/02/2010

### ABSTRACT

Spontaneous pneumoperitoneum in patients undergoing haemodialysis is usually associated with non-occlusive mesenteric ischaemia or prior instrumental diagnostic tests. We present the case of an 88 year-old man on chronic haemodialysis with spontaneous pneumoperitoneum secondary to conservatively-managed benign idiopathic pneumatosis intestinalis, with favourable outcome.

#### Key-Words:

Haemodialysis; pneumatosis intestinalis; pneumoperitoneum.

### CASE REPORT

Spontaneous pneumoperitoneum (SP) in patients on haemodialysis (HD) without prior surgery or instrumental abdominal examinations is an uncommon condition usually associated with non-occlusive mesenteric ischemia. It is generally associated with hypovolaemia, low blood pressure and mesenteric vasoconstriction with advanced atherosclerotic disease. We present a case of SP whose aetiology differs from the above, with favourable clinical outcome.

The patient in question was an 88 year-old male who had been on chronic HD for one year. He had

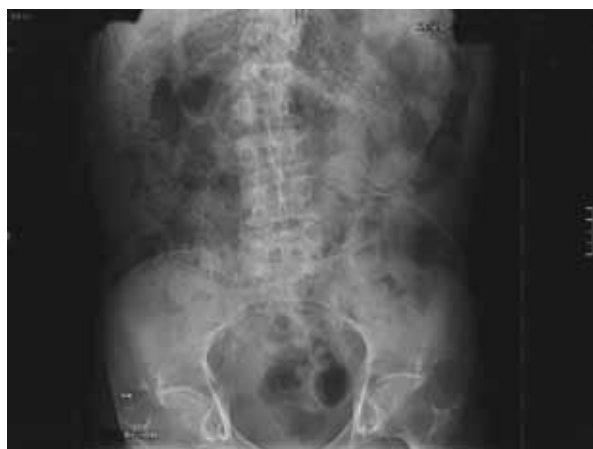a background of pneumotoxic induced lung fibrosis, chronic obstructive pulmonary disease (COPD), hypertension, type 2 diabetes mellitus (DM) and chronic constipation of multifactorial aetiology. The aetiology of his end-stage renal disease was nephrosclerosis on a single kidney with contralateral atrophy of unknown cause. Three months earlier he had suffered two episodes of cholecystitis secondary to cholelithiasis which were resolved conservatively. The patient was pending scheduled cholecystectomy.

He was treated with erythropoietin alpha, iron sucrose, enalapril, acetylcysteine, insulin, calcitriol, acetylsalicylic acid, omeprazole, calcium carbonate and inhaled salmeterol and ipratropium.

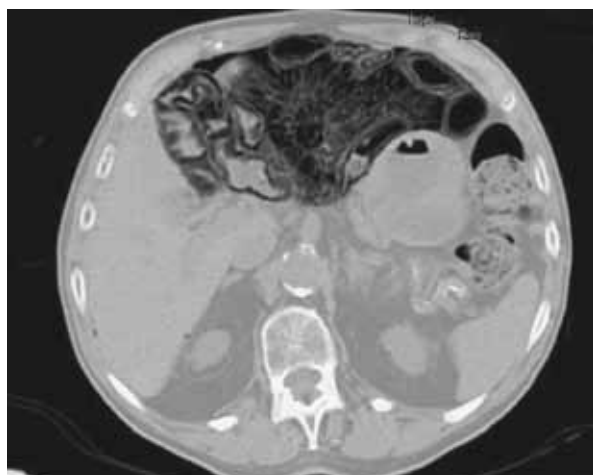Seven days prior to his visit he experienced progressive abdominal pain accompanied by continuous and diffuse nausea, progressive and accentuated constipation and abdominal fullness, and was apyretic. The physical examination showed blood pressure of 140/90, axillary temperature 36.4°C, O<sub>2</sub> saturation 98%, good hydration and perfusion, conserved general condition. Hickman type in-dwelling subclavium catheter for haemodialysis was in good condition. Heart rate was 84 bpm, rhythmic, decreased vesicular murmur in bases with low pitched wheezes and dispersed whistling rales in right base, present during previous examinations, non-painful abdomen, rebound and guarding, no observable zones of dull sounds or tympanism and conserved air-fluid levels. Lower limbs were without

oedema or signs of peripheral venous thrombosis. His constipation continued and he was treated with oral paraffin. He was haemodynamically stable both during and between dialysis sessions. Laboratory tests did not reveal any significant abnormalities in the liver or pancreatic function or leucocytosis. Blood gas measurement showed no signs of metabolic acidosis and lactic acid levels were normal.

The X-ray (Fig. 1) and abdominal CT scan (Fig. 2) showed pneumoperitoneum on the perihepatic level as well as intramural gases in the adjacent small



**Figure 1**  
Abdominal X-ray



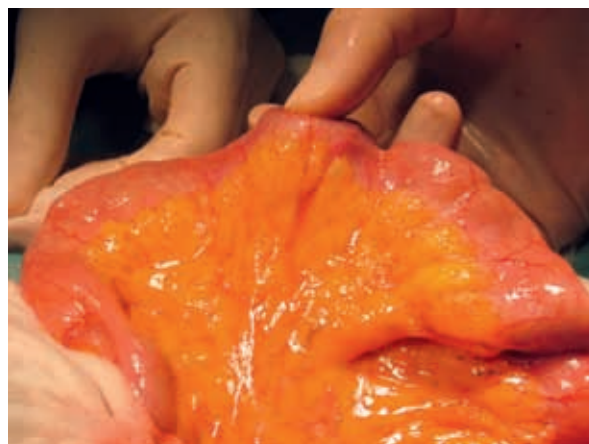
**Figure 2**  
Abdominal CT scan

bowel loops. Diagnostic suspicion was established as cystic pneumatosis intestinalis. Given the acceptable general condition and age of the patient, conservative treatment was initiated using parenteral nutrition, broad-spectrum antibiotics (ceftriaxone and metronidazole) and respiratory support with high flow oxygen. The patient's evolution was satisfactory, with improvement of his digestive and general health. The programmed laparotomy was performed one week later, during which a cholecystectomy was performed and the intestinal loops examined.

Presence of perforation, ischaemia or intestinal distress was ruled out and the presence of cysts in the intestinal wall confirmed (Fig. 3). The postoperative period was uneventful with no complications and enteral and oral nutrition was progressively reintroduced. Treatment with ceftriaxone was suspended after 15 days and oral metronidazole was maintained for three months with progressive clinical and radiological resolution of the picture.

The patient remained asymptomatic and was in good general condition six months after surgery.

The differential diagnosis of SP<sup>1,2</sup> takes into consideration thoracic (mechanical ventilation, pneumothorax, COPD, tracheal rupture, cardiopulmonary resuscitation, asthma) and abdominal causes (inflammatory bowel disease, necrotising enterocolitis, perforated hollow viscera, ischaemic bowel, penetrating injury, abdominal Hirschsprung's disease, pelvic manipulation, etc.) as well



**Figure 3**  
Presence of cysts in the intestinal wall

as conditions secondary to abdominal surgical instrumentation and other diseases not included in these sections (cocaine ingestion, dental extraction, decompression diving accident, etc.). The cause is primary in 15% of cases, and 85% are secondary to systemic disease (collagen disease, bone marrow transplantation or cardiac neoplasms, inflammatory bowel disease, AIDS, clostridium infection, tuberculosis, cytomegalovirus, cryptosporidium, Whipple's disease, etc.).

Pneumatosis intestinalis<sup>3</sup> is a benign idiopathic condition characterised by the presence of multiple gas-filled cysts, basically hydrogen, with submucosal or subserosal location mainly in the terminal ileum, whose rupture leads to pneumoperitoneum. This can be explained by three possible hypotheses. The first, bacterial, states that it is caused by a gas-producing bacterial superinfection (*E. Coli*, *Clostridium* and others). The second, mechanical, suggests that there is air passage from the lung or bowel wall through the microruptures of the intestinal surface through the mesenteric vessels. The third, biochemical, posits that the fermentation of carbohydrates, which produces gas that passes through the intestinal wall and reaches the submucosa by pressure, is the underlying cause. Some factors, such as DM, alpha-glucosidase inhibitors or lactulose consumption, may accentuate this mechanism.

Symptoms consist of abdominal pain, constipation or diarrhoea, vomiting and rectal tenesmus. A small percentage of patients (3%) may have serious complications such as bowel obstruction, gastrointestinal bleeding, volvulisation, perforation, sepsis or mesenteric ischaemia. Diagnosis by imaging tests can be performed via simple abdominal X-ray, in which linear, curvilinear or circumferential gas collections appear in the circumference of the intestinal wall. Furthermore, portal pneumatosis, with collections of "branched" gas in the theoretical hepatic location, may sometimes be distinguished. Its location adjacent to the wall lumen can be distinguished with greater accuracy with CT scan, without the appearance of the air-fluid level present in the intestinal lumen or the location inside the portal tree. Two morphological patterns have been described; multiple rounded bullae, at first seemingly benign and having good evolution, and the linear collections more frequently related with more serious clinical pictures and worse evolution<sup>10</sup>.

There are many cases in the literature of pneumatosis intestinalis in patients with normal renal function<sup>4-6</sup>

and related to peritoneal dialysis, but these cases are rare in HD<sup>7-9</sup>. The latter generally occurs in patients with poor evolution, in those with an underlying disease of arterial ischaemia, atherosclerosis and vascular calcifications, with increased risk of infections by gas-forming bacteria and impaired immune response (uraemia, DM, etc.)<sup>7,8</sup>. Clinical pictures of idiopathic origin mostly involve the colon, but cases of small intestine involvement have been described<sup>2,4,9</sup>. Treatment is based on the administration of high flow or hyperbaric oxygen, elemental low carbohydrate diet and broad-spectrum antibiotics for prolonged periods.

Our case is unique due to its association with the advanced age of the patient, the presence of pulmonary disease and previous severe abdominal disease, the fact that the patient is in chronic HD and his excellent evolution with conservative treatment, including the possibility of a certain diagnosis through laparotomy.

**Conflict of interest statement.** None declared.

## References

- Mularski RA, Sippel JM, Osborne ML. Pneumoperitoneum: A review of non surgical causes. *Crit Care Med* 2000;28:2638-2644
- Daly BD, Guthrie JA, Couse NF. Pneumoperitoneum without peritonitis. *Postgrad Med J* 1991;67:999-1003
- García-Cabrera AM, García-Padial F, Jiménez-Ríos JA, et al. Neumatosis intestinal y gas portal secundarios a obstrucción de origen adherencial. *Cir Esp* 2005;78:392-5
- Gimeno Cabanes RM, Alonso Formento E, Galindo Dobón M, López Peris PV, Fernández Merlo MA, Carot Gil MT. Neumatosis quística intestinal primaria como causa de neumoperitoneo benigno. *Emergencias* 2006;18:303-305
- González Rodríguez JF, Seoane RA, San Luis Calo E, Potel Lesquereaux J. Neumatosis portal en un paciente en programa de hemodiálisis. *Cir Esp* 2008;83:212-219
- Christensen LA, Schmidt EB, Mortensen PB, Højhus JH. Pneumatosis intestinales in a patient on chronic haemodialysis treatment. *Nephrol Dial Transplant* 1989;4:745-747
- Coşkun F, Coşkun F, Aksu NM, et al. Non-occlusive mesenteric ischemia in a chronic dialysis patient: a case report. *Ulus Travma Acil Cerrahi Derg* 2008;14:256-259
- Suzuki H, Murata K, Sakamoto K. An autopsy case of fulminant sepsis due to pneumatosis cystoides intestinalis. *Leg Med (Tokyo)* 2009;11:528-530.
- Anne N, Rajput A, Dunn KB, Litwin A. Idiopathic pneumatosis intestinalis of the small intestine. *Am Surg* 2008;74:1127-1129
- Soyer P, Martin-Grivaud S, Boudiaf M, et al. Linear or bubbly: a pictorial review of CT features of intestinal pneumatosis in adults. *J Radiol* 2008;89:1907-1920

## Correspondence to:

Dr. Juan Martín Navarro  
Servicio de Nefrología, Hospital del Tajo  
Av. Amazonas Central s/n  
28300 Madrid, Spain  
e-mail: juanmartinnav@hotmail.com