

Secondary pseudohypoaldosteronism in an infant with malformative uropathy

Ana L. Leite, António V. Silva, António C. Vilarinho, Graça Ferreira

Department of Paediatrics, Centro Hospitalar Gaia/Espinho, Portugal.

Received for publication: 18/08/2009
Accepted in revised form: 31/10/2009

■ ABSTRACT

Introduction. Malformative uropathy is not uncommon in infants and is in the main identified by antenatal ultrasound. It can be associated with multiple complications such as chronic renal failure later in life, but also acute life threatening events such as secondary pseudohypoaldosteronism.

Case Report. We present a case of a boy with obstructive uropathy who developed two distinct episodes of hyperkalaemia, hyponatraemia and metabolic acidosis, revealing a state of unresponsiveness to aldosterone. Both were imbalanced by urinary tract infection and malformative uropathy and occurred early in life (first in the neonatal period and second at the age of three months).

Conclusion. Obstructive uropathy and/or infected vesicoureteral reflux should be considered in differential diagnosis of this threatening condition and prompt renal ultrasonography, urine culture, and assays of aldosterone and renin allow early diagnosis and treatment approaches.

Key-Words:

Hyperkalaemia; hyponatraemia; malformative uropathy; secondary pseudohypoaldosteronism; urinary tract infection.

■ INTRODUCTION

Pseudohypoaldosteronism (PHA) is a rare syndrome characterised by a state of renal tubular unresponsiveness to aldosterone and is manifested by hyperkalaemia, hyponatraemia and metabolic acidosis^{1,2}.

PHA can be either a primary (hereditary) or secondary (acquired) condition. The secondary form of PHA was initially described in 1983 by Rodriguez-Soriano *et al.*¹. These authors described a group of children with poor weight gain, vomiting and dehydration, along with uropathy malformation and urinary tract infection.

We discuss a case of an infant with known malformative uropathy who developed two subsequent transient episodes of secondary PHA accompanied by urinary tract infections.

■ CASE REPORT

A male, first-born baby of non-consanguineous parents, with antenatal ultrasound diagnosis of bilateral ureterohydronephrosis was delivered vaginally, at 36 weeks gestation, with Apgar 7/9, with no need of reanimation. Anthropometry at delivery

was appropriate for the gestational age (W-3000g, Percentile 10-25; H-49cm, Percentile 25; HC-34cm, Percentile 10-25).

On the 2nd day of life he underwent renal ultrasound which revealed “pelvis duplication of both kidneys, with bilateral dilation of the lower part; parenchymal atrophy of lower pole of both kidneys; large bladder and with concentric parietal thickening”. He then underwent voiding cystourethrogram (VCUG) that confirmed severe congenital bilateral vesicoureteral reflux grade V (Fig. 1) and initiated prophylactic trimethoprim.

He had a paediatric nephrology consultation on the 28th day of life due to poor weight gain (W 2925g, Percentile <5), vomiting and polyuria. On admission, he was pale and dehydrated with genitals of normal colour and appearance.

Analysis revealed leucocytosis, azotaemia, severe hyponatraemia, hyperkalaemia and, metabolic acidosis with normal anion gap (slightly corrected by respiratory alkalosis). Endocrinologic study showed markedly elevated plasma aldosterone and renin concentrations, while cortisol and 17- α -OH-progesterone were normal (Table I). Urinalysis revealed turbid urine with leucocytosis and haematuria. Despite dehydration, polyuria was confirmed in the first days of internal (7mL/Kg/hour). In the 3rd day at the hospital, *Enterococcus faecalis* was isolated from urine culture. Renal ultrasonography confirmed bilateral severe ureterohydronephrosis.

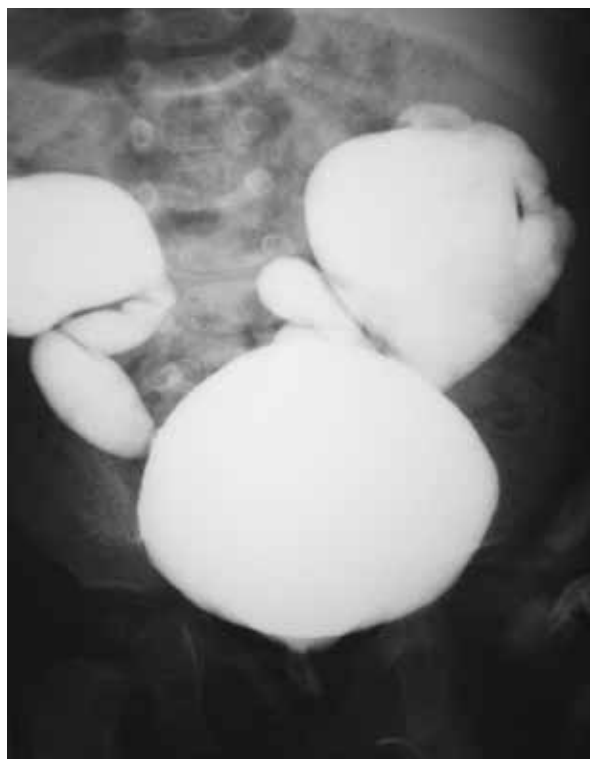


Figure 1

Voiding cystourethrogram demonstrating congenital megaureter with bilateral grade V vesicoureteral reflux.

Antibiotic therapy was initiated (cefuroxime + gentamicine i.v.), as well as therapy for the electrolyte imbalance, with progressive clinical improvement. At day 14 normal electrolytic status was regained. He

Table I

Laboratory data for the first secondary pseudohypoaldosteronism episode, during the neonatal period.

	Admission	D 9	D 14	Reference values*
Na ⁺	108 ↓	135.1	140.0	134-146 (mmol/L)
K ⁺	7.7 ↑	6.10	5.7	3.0-7.0 (mmol/L)
Cl ⁻	87 ↓	98	101	97-110 (mmol/L)
pH*	7.304 ↑	7.337 ↓	-	7.350-7.450
pO ₂ *	35	52.2	-	35-45 (mmHg)
pCO ₂ *	30	43	-	30-40 (mmHg)
HCO ₃ ^{-*}	14.5 ↓	22.4	-	22.0-29.0 (mmol/L)
BE*	-10.6 ↑	-2.5	-	(-10)-(-2) (mmol/L)
BUN	30.0 ↑	-	4.1	1.1-4.3 (mmol/L)
Creatinine	44.2	-	←15.0	27.0-88.0 (μmol/L)
Cortisol	38.7	-	-	28.0-662.0 (nmol/L)
17-OH-progesterone	3.8	-	-	1.9-11.0 (nmol/L)
Aldosterone	>14.0 ↑	-	4.59 ↑	0.14-2.50 (nmol/L)
Renin	38.9 ↑	-	11.6 ↑	0.5-5.2 (pmol/L)

* Venous blood

maintained urinary catheter and after recovery underwent vesicostomy.

At discharge (after five weeks of admission), aldosterone and renin were slightly elevated, but they no longer caused electrolytic disturbances.

At the age of three months, he developed another episode of secondary pseudohypoaldosteronism, caused by another urinary tract infection, which was promptly diagnosed and correctly treated. At nine months of age he is currently clinically stable, with normal aldosterone and renin values, and taking prophylactic antibiotic with cotrimoxazol.

DISCUSSION

Foetal hydronephrosis caused by ureteropelvic junction obstruction, as detected by antenatal ultrasound screening, has an incidence of nearly 1 in 500 live births. Males are predominantly affected and obstruction may be bilateral in 10 to 40% of the cases^{3,4}. In the case reported, the neonate presented a congenital megaureter (his ureter exceeds 7mm in diameter) and a grade 5 bilateral reflux, making his condition an obstructive refluxing congenital megaureter⁵.

In 1983, Rodriguez-Soriano *et al.*¹ first demonstrated a relationship between infected obstructive uropathy and a rare clinical entity called secondary pseudohypoaldosteronism. This clinical entity is characterised by serious disturbances of water and acid-base concentrations, caused by renal tubular unresponsiveness to aldosterone, and explains the common markedly elevated concentrations of aldosterone and renin⁶.

More recently, in 2003, Wanatabe⁷ reviewed 60 cases of secondary PHA previously reported in the literature and concluded that all patients were less than 7 months old, 80% of them suffered from urinary tract malformations and UTI, analogous to our case; 11.7% had urinary tract malformation without UTI and 8.3% had only isolated UTI. He therefore proposed that secondary PHA occurs in children with immature renal tubular responsiveness to aldosterone, due to urinary tract malformation and/or UTI, during infancy.

In the reported case, both episodes of secondary PHA (first in the neonatal period and the other at

three months of age) occurred at a period of great immaturity. In addition, this patient had severe obstructive uropathy and UTI despite prophylactic antibiotic therapy with trimethoprim. Although he developed subsequent transient serious electrolytic imbalance, it was fully reversed with appropriate and early antibiotic therapy. In fact, all these parameters match with what is described in the literature for secondary PHA. Unfortunately, urinary ions (potassium and sodium) and anion gap were not measured at admission, enabling us to complement the aldosterone impact on tubular renal function.

The pathogenesis of this acquired and transient condition is still unknown. In 2006, Asano *et al.*⁸ proposed two theories to justify this mechanism. The obstructive uropathy theory proposes that high intrarenal pressure might lead to great production of cytokines or, alternatively, would reduce renal outflow, activating the angiotensin-aldosterone cascade, which would lead to high aldosterone values. Secondly, the urinary tract infection theory proposes that infection, directly or not, is responsible for renal interstitial inflammation, contributing to tubular unresponsiveness to aldosterone activity.

In the first episode of secondary PHA reported, our patient showed plasmatic aldosterone values persistently elevated, even after treatment. Then, a small imbalance (such as UTI) triggers the development of another secondary PHA, as occurred in the second episode described. This situation has also been previously reported by Marra *et al.*⁹.

Recently more cases of aldosterone resistance simply in the setting of a urinary tract infection have been reported^{10,11}. Some authors, however, question whether the malformative uropathy is due to their high incidence in infants diagnosed with severe urinary tract infections and not one of the main cause itself¹².

In conclusion, with this report, we emphasise the need to consider secondary pseudohypoaldosteronism as a differential diagnosis in infants who develop hyponatraemia, hyperkalaemia and metabolic acidosis, especially when there is malformative uropathy. Early diagnosis is possible by performing assays of aldosterone and plasma renin, urine culture and renal ultrasound.

Conflict of interest statement. None declared.

Acknowledgements. To Sílvia Vilarinho, for her help in the grammar of this article.

References

1. Rodriguez-Soriano J, Vallo A, Quintela MJ, Oliveros R, Castillo G. Transient pseudohypoaldosteronism secondary to obstructive uropathy in infancy. *J Pediatr* 1983;103:375-380
2. Maruyama K, Wanatabe H. Reversible secondary pseudohypoaldosteronism due to pyelonephritis. *Pediatr Nephrol* 2002;17:1069-1070
3. Liang CC, Cheng PJ, Lin CJ. Outcome of prenatally diagnosed fetal hydronephrosis. *J Reprod Med* 2002;47:27-32
4. Morin L, Cendron M, Crombleholme TM, Garmel SH. Minimal hydronephrosis in the fetus: clinical significance and implications for management. *J Urol* 1996;155:2047-2049
5. Cussen LJ. Dimensions of the normal ureter in infancy and childhood. *Invest Urol* 1967;5:164-178
6. Wanatabe T, Yamazaki A. Pneumothorax and transient pseudohypoaldosteronism in an infant with hydronephrosis. *Pediatr Nephrol* 2003;18:62-64
7. Wanatabe T. Reversible secondary pseudohypoaldosteronism. *Pediatr Nephrol* 2003;18:486
8. Asano T, Abe M, Asai M, Imai T, *et al.* Urinary tract malformation and infection with hyperkalemia and decreased fractional excretion of potassium in an infant. *J Nippon Med Sch* 2006;73:289-291
9. Marra G, Goj V, Appiani AC, *et al.* Persistent tubular resistance to aldosterone in infants with congenital hydronephrosis corrected neonatally. *J Pediatr* 1987;110:868-72
10. Rogers D. Final diagnosis: transient pseudohypoaldosteronism. *Clin Pediatr (Phila)* 2008;47:405-408
11. Kashimada K, Omori T, Takizawa F, Mizutani S. Two cases of transient pseudohypoaldosteronism due to group B streptococcus pyelonephritis. *Pediatr Nephrol* 2008;23:1569-70
12. Nandagopal R, Vaidyanathan P, Kaplowitz P. Transient Pseudohypoaldosteronism due to Urinary Tract Infection in Infancy: A Report of 4 Cases. *Int J Pediatr Endocrinol* 2009; doi: 10.1155/2009/195728

Correspondence to:

Dr Ana L. Leite
Department of Paediatrics
Centro Hospitalar Gaia/Espinho
Rua Dr. Francisco Sá Carneiro
4400-129 Vila Nova de Gaia, Portugal
E-mail: ana.luisa20@gmail.com