

Tubulointerstitial nephritis associated with hepatitis C virus infection

Ana Oliveira, Raquel Cabral, Susana Sampaio, Manuela Bustorff, Manuel Pestana

Department of Nephrology, Hospital São João. Porto, Portugal.

Received for publication: 11/12/2008

Accepted in revised form: 20/03/2009

ABSTRACT

Chronic hepatitis C virus infection is frequently associated with extrahepatic diseases that in most cases appear to be directly related to the viral infection. Renal disease is one of the most common extrahepatic manifestations. The disorder is predominantly glomerular and includes membranoproliferative glomerulonephritis, with or without associated mixed cryoglobulinaemia and membranous nephropathy.

We report a case of a patient with hepatitis C virus infection, with multiple extrahepatic manifestations including monoclonal gammopathy, lower limbs vasculitis, Sjögren's syndrome and tubulointerstitial nephritis. In this case, we describe a rare renal manifestation of hepatitis C virus infection: tubulointerstitial nephritis.

Key-Words:

Hepatitis C virus (HCV), Sjögren's syndrome, tubulointerstitial nephritis.

INTRODUCTION

Hepatitis C virus (HCV) infection leads to chronic liver disease, frequently associated with several extrahepatic manifestations¹. These include haematological, dermatological and renal diseases². Although the mechanisms of how HCV induces these disorders are not known, there is evidence that

extrahepatic virus invasion and replication and immunological mechanisms are involved^{1,3}.

There is a strong and most likely causal association between chronic HCV infection and glomerular disease. The principal type of renal manifestation of HCV infection is membranoproliferative glomerulonephritis (MPGN), usually in the context of cryoglobulinaemia⁴. Less frequently described lesions include MPGN without cryoglobulinaemia and membranous glomerulonephritis. Also, occasional cases of focal segmental glomerulosclerosis, thrombotic microangiopathy associated with anticardiolipin antibodies and fibrillary and immunotactoid glomerulopathies have been reported⁴⁻⁶.

Sjögren's syndrome is a multisystemic autoimmune disease which predominantly affects the exocrine glands and it occurs in a primary or secondary form⁷. In patients with chronic HCV infection, a lymphocytic sialadenitis suggestive of Sjögren's syndrome has been described¹. Chronic HCV infection should be considered an exclusion criterion for the classification of primary Sjögren's syndrome, not because it mimics primary Sjögren's syndrome, but because the virus may be implicated in the development of Sjögren's syndrome in a specific subset of patients⁸. The immune process associated with Sjögren's syndrome can also affect nonexocrine organs, including the kidneys. The major renal manifestation is a chronic interstitial nephritis⁹. Less common manifestations are type 1 renal tubular acidosis and nephrogenic diabetes *insipidus*⁹.

We present a case of a patient with hepatitis C virus infection, monoclonal gammopathy lower limbs vasculitis and Sjögren's syndrome with chronic interstitial nephritis.

■ CASE REPORT

We present a 55 year-old Caucasian male with blood transfusion acquired HCV infection diagnosed in 1997. He had elevated transaminase levels and HCV RNA, by polymerase chain reaction (PCR), of 110613 IU/ml. The HCV genotype was 1b. In the same year a liver biopsy was performed, that revealed mild portal fibrosis, piecemeal necrosis and mild-to-moderate necro-inflammatory intralobular lesions and he started α -interferon 5000 U three times a week. After 8 months of treatment, α -interferon was stopped because there was no clinical-laboratory response. Combined therapy with ribavirin was not instituted because of an irregular follow-up and he was out of treatment until 2007. In 2004, the patient presented with parotid enlargement and xerostomia was diagnosed, without further study.

In 2006, two years later, he was referred to the Nephrology department with renal insufficiency. The pertinent findings on physical examination included a chronically ill appearance, normal blood pressure, cutaneous vasculitis lesions in his lower limbs (Fig.

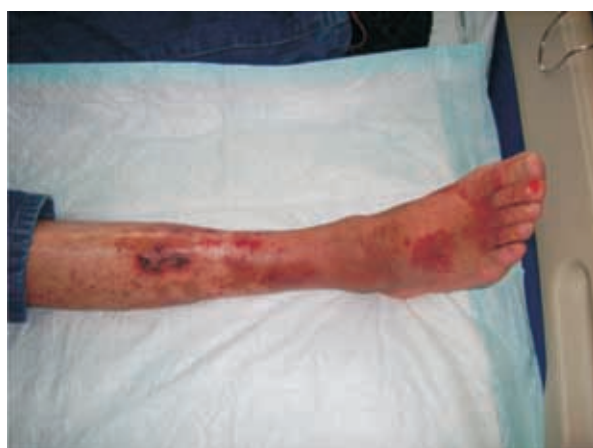

Figure 1

Palpable purpura and small ulcerated areas in the lower extremities.

1) and there was no evidence of ascitis or other signs of liver disease. Review of his records showed an increase in serum creatinine levels from normal to 2.37 mg/dl during a two-year period. He had mild proteinuria of 903 mg/day and the urinalysis showed leucocyturia without haematuria. Renal ultrasound revealed normal kidneys size with increased ecogenicity. Laboratory tests showed anaemia with a haemoglobin level of 10.5 g/dl, elevated erythrocyte sedimentation rate of 100 mm/h, elevated total proteins (10.2 g/dL), low serum albumin (3.22 g/dL), elevated transaminases levels (SGOT 85 U/L, SGPT 101 U/L) and alkaline phosphatase (254 U/L), normal bilirubin and coagulation profile. Immune assays were a positive ANA (title of 1/1000 with a spotted pattern) with negative anti-double-stranded DNA antibodies, positive rheumatoid factor (3590 IU/ml) and anti-SSA and SSB antibodies, and a monoclonal IgM/Kappa gammopathy. Complement C3 and C4 levels were normal. Cryoglobulins and urine immunofixation were negative. There was no evidence of hepatitis B or human immunodeficiency virus (HIV) infection. The HCV RNA by PCR was 16800 IU/ml. There was no amyloid substance in the abdominal fat. An upper endoscopy revealed esophagic varices, but the patient never presented gastrointestinal bleeding.

The bone marrow biopsy revealed reactional alterations, without signs of malignancy. The abdominal CT scan showed enlarged liver and spleen without ascitis or adenomegalies

The renal biopsy was compatible with tubulointerstitial nephritis and presented mild and focal mesangial proliferation with two of the 19 glomeruli globally sclerosed, marked tubulointerstitial lesions with a predominantly mononuclear cell infiltrate in 70% of the parenchyma, and tubular atrophy and interstitial fibrosis in 20% of the parenchyma (Fig. 2). Immuno-histochemistry revealed that approximately 80% of the infiltrate corresponded to T lymphocytes (with a majority of CD4) and 20% to B lymphocytes. Immunofluorescence was positive for IgM and fibrinogen. Electron microscopy did not show immune complex deposits.

The salivary gland biopsy, performed after complaints of sicca symptoms and parotid enlargement, revealed glandular atrophy with lymphocytic infiltration, compatible with Sjögren's syndrome.

Considering the histological lesions present in the performed liver biopsy in 1997 and the presence of esophageic varices, a liver biopsy was not repeated.

The patient started treatment with pegylated interferon α -2a (135 μ g/week SQ) with a good virologic response as he had nondetectable HCV RNA at the 12th week. There was clinical improvement of cutaneous vasculitis and an apparent improvement in renal function with a decrease of serum creatinine from 2.76 mg/dl before starting treatment to 2.17 mg/dl at last follow-up. Pegylated interferon α -2a was well tolerated except for mild leucopaenia, with neutrophils count between 1100 and 1500/mL³

In the 8th month of treatment his lower limb ulcers reappeared and he developed a septic shock due to methicillin resistant *Staphylococcus aureus* secondary to lower limb infected ulcers and died.

DISCUSSION

Mixed cryoglobulinaemia is associated in 90% of cases with chronic HCV infection⁵. It is an entity whose full picture is characterised by purpuric-vasculitic skin lesions, Raynaud's phenomenon, arthralgias, peripheral neuropathy, glomerulopathy and even systemic vasculitis. The majority of patients have elevated rheumatoid factor and low levels of complement, especially C₄ levels. The most frequent presenting renal syndrome is isolated proteinuria with microscopic haematuria, sometimes associated with mild to moderate chronic renal insufficiency or, less frequently proteinuria in the nephrotic range or an acute nephritic syndrome. The corresponding histological picture is MPGN, with marked glomerular inflammatory cell infiltrates and lobulation of the tuft architecture. Subendothelial immune complexes are present in electron microscopy.

Some patients with HCV infection have MPGN without cryoglobulinaemia (30-50%). The presence of cryoglobulins helps in the differential diagnosis. In this case features of leucocytic infiltration and intracapillary immune aggregates are less apparent or absent.

Membranous nephropathy is another disorder that may be induced by chronic HCV infection, but this

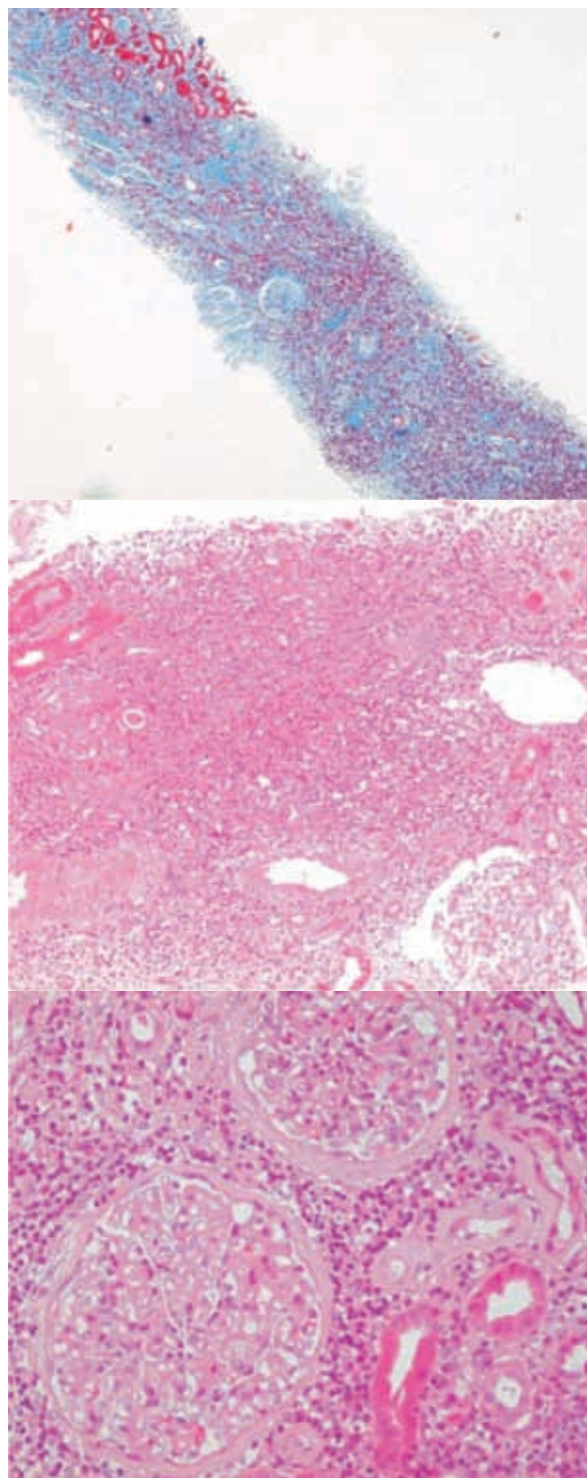


Figure 2

Renal biopsy showing marked tubulointerstitial lesions with a predominantly mononuclear cell infiltrate in 70% of the parenchyma, and tubular atrophy and interstitial fibrosis in 20% of the parenchyma.

is rare. In contrast to the findings in mixed cryoglobulinaemia or MPGN, complement levels tend to be normal and neither cryoglobulins nor rheumatoid factor are present in HCV-associated membranous nephropathy¹⁰.

In our patient, the presence of lower limb vasculitis, renal insufficiency with proteinuria and positive rheumatoid factor, raised the possibility of cryoglobulinaemia. However he had no haematuria, hypocomplementaemia or positive cryoglobulins. A positive rheumatoid factor and the absence of nephrotic proteinuria made the hypothesis of membranous nephropathy less likely. As he had a monoclonal gammopathy associated with proteinuria and renal insufficiency, a diagnosis of dysproteinaemia or amyloidosis related renal disease was another possibility. The absence of amyloid substance in the abdominal fat as well as the results of urine immunofixation and renal biopsy excluded these hypotheses.

In addition to renal involvement, the patient had many of the extrahepatic manifestations of hepatitis C chronic infection, namely Sjögren's syndrome, monoclonal gammopathy without evidence of haematologic neoplasia and cutaneous vasculitis of the lower extremities. He also had positive ANA, which is described in 40-65% of patients with HCV infection¹.

Sjögren's syndrome when associated with HCV infection has some differences from primary Sjögren's syndrome, namely the absence or presence of a lower titre of anti-SSA and anti-SSB antibodies, the presence of a positive rheumatoid factor frequently associated with cryoglobulin and hypocomplementaemia and extraglandular manifestations are more frequent in HCV associated Sjögren's syndrome^{8,11}. Our patient had positive anti-SSA and anti-SSB antibodies, extraglandular manifestations, but no cryoglobulin or hypocomplementaemia.

We describe an unusual type of renal manifestation associated with hepatitis C virus infection. In patients with hepatitis C chronic infection associated with Sjögren's syndrome the diagnosis of tubulointerstitial nephritis should always be considered. However it should be emphasised that HCV positive patients with glomerulopathy have greater areas of interstitial fibrosis and inflammatory cell infiltration than HCV-negative patients¹². It was not possible to

perform *in situ* hybridisation or immuno-histochemistry for HCV-RNA. This would have been useful as HCV-RNA is described as a direct pathogenic factor of tubulointerstitial lesions¹².

Therapeutic management of patients with HCV and systemic autoimmune diseases has become a clinical challenge in HCV infected patients. Both anti-viral and immunosuppressive therapies, either alone or in combination, seem likely to have a key role, although treatment should be tailored according to cost, follow-up, relapses, organ involvement, risk of exacerbation of autoimmune disease and the possible consequences of immunosuppression in the setting of chronic HCV infection¹³. The treatment of interstitial nephritis in primary Sjögren's syndrome with corticosteroids is uncertain since only occasional cases of renal tubular acidosis and/or renal insufficiency remitted with steroid therapy⁹. We decided not to start that therapy because the patient had active and marked viral replication. He started peginterferon not associated with ribavirin, as his glomerular filtration rate was below 50 mL/min/1.73m², given the higher risk of haemolytic anaemia. A good virological and clinical response was observed although he had reappearance of limb ulcers, which could be a relapse of the dermatological manifestations of HCV infection; we can argue that we should have initiated corticosteroids in that phase, but it was decided not to start as he had a septic shock caused by methicillin resistant *Staphylococcus aureus*.

Although glomerular disease is the mainly renal manifestation associated with HVC infection, in patients with serum and urinary abnormalities suggestive of tubulointerstitial lesion, the diagnosis of Sjögren's syndrome with tubulointerstitial nephritis should be considered. Tubulointerstitial nephritis should be included in the differential diagnosis of renal diseases associated with hepatitis C virus infection.

Conflict of interest statement. None declared.

References

- Galossi A, Guarisco R, Bellis L, Puoti C. Extrahepatic Manifestations of Chronic HCV Infection. *J Gastrointest Liver Dis* 2007;16:65-73
- Lauer GM, Walker BD. Hepatitis C virus infection. *N Engl J Med* 2001;345: 41-52
- Sugal S. Hepatitis C Virus and Sjögren's Syndrome. *Intern Med* 2005;44:533-5

4. Kamar N, Rostaing L, Alric L. Treatment of hepatitis C-virus-related glomerulonephritis. *Kidney Int* 2006;69:436-439
5. Meyers CM, Seeff LB, Stehman-Breen CO, Hoofnagle JH. Hepatitis C and renal disease: an update. *Am J Kidney Dis* 2003;42:631-657
6. Johnson RJ, Willson R, Yamabe H, *et al.* HCV and glomerulonephritis. *Kidney Int* 1994;46:1255-1263
7. Vitali C, Bombardieri S, Jonsson, *et al.* Classification criteria for Sjögren's syndrome: a revised version of the European criteria proposed by the American-European consensus group. *Ann Rheum Dis* 2002;61:554-558
8. Ramos-Casals M, Loustand-Ratti V, De Vita S, *et al.* Sjögren syndrome associated with hepatitis C virus: A Multicenter Analysis of 137 Cases. *Medicine (Baltimore)* 2005;84:81-89
9. Bossini N, Savoldi S, Franceschini F, *et al.* Clinical and morphological features of kidney involvement in primary Sjögren's syndrome. *Nephrol Dial Transplant* 2001;16:2328-2336
10. Stehman-Breen C, Alpers CE, Couser WG, *et al.* Hepatitis C virus and membranous glomerulonephritis. *Clin Nephrol* 1995; 44:141
11. Ramos-Casals M, Garcia-Carrasco M, Cervera R, *et al.* Hepatitis C virus infection mimicking primary Sjögren syndrome. A clinical and immunologic description of 35 cases. *Medicine* 2001;80:1-8
12. Kasuno K, Ono T, Matsumori A, *et al.* Hepatitis C Virus- Associated Tubulointerstitial Injury. *Am J Kidney Dis* 2003;41:767-775
13. Ramos-Casals M, Jara LJ, Medina F, *et al.* Systemic autoimmune diseases co-existing with chronic hepatitis C virus infection (the HISPAMEC Registry): patterns of clinical and immunological expression in 180 cases. *J Int Med* 2005;257:549-557

Correspondence to:

Dr Ana Oliveira

Rua Visconde de Setúbal, 133

4200-499 Porto, Portugal

E-mail: nocas.cortereal@gmail.com