

Acute renal failure with renal replacement therapy – a rare complication in HELLP syndrome

Ana T. Boquinhas, João Colaço, Isabel R. Carvalho, Isabel Simões, Eduarda Carmo, Isabel Gaspar, José L. Neves, Eduardo Monteiro

Unidade de Cuidados Intensivos Polivalente, Hospital de Egas Moniz.
Centro Hospitalar de Lisboa Ocidental. Lisbon, Portugal.

Received for publication: 09/01/2007

Accepted in revised form: 29/04/2008

■ ABSTRACT

HELLP (Haemolysis, Elevated Liver enzyme levels and Low Platelet count) syndrome occurs in 1 in 1000 pregnancies. Acute renal failure is a rare but severe complication.

The authors report the case of a previously healthy 33 year-old black woman who had had two previous normal pregnancies. Patient presented with 32 weeks of uneventful pregnancy and developed hypertension, acute renal failure and transient disseminated intravascular coagulation, part of a HELLP syndrome. Treatment included haemodiafiltration, red blood cell transfusions, corticosteroids and sodium nitroprusside, with gradual and complete recovery in 14 days.

Acute renal failure needing renal replacement therapy can occur in approximately 2 to 5% of patients with HELLP syndrome and can be misdiagnosed as another similar condition such as acute fatty liver of pregnancy, haemolytic-uraemic syndrome or thrombotic thrombocytopenic purpura. The pathogenic process is not fully understood, but is believed to be associated with endothelial damage and thrombotic microangiopathy, resulting in acute tubular necrosis. The outcome is generally good when management is in a specialised centre and includes continuous monitoring of labour, prompt delivery and supportive therapy.

Key-Words:

Acute renal failure; HELLP syndrome.

■ INTRODUCTION

HELLP syndrome (Haemolysis, Elevated Liver enzyme levels and Low Platelet count) is an obstetric complication defined as a variant of pre-eclampsia, although it may be considered a distinct entity, frequently leading to a misdiagnosis on initial presentation. It was first described in 1982 and is considered to affect 1 in 1000 pregnancies¹. Acute renal failure (ARF) needing renal replacement therapy, with serum creatinine levels above 4mg/dl, is an unusual complication and can occur in 2 to 5% of gestations with HELLP syndrome^{2,3}.

We report a case of HELLP syndrome, complicated with ARF, requiring renal replacement therapy. We discuss the difficulties of differential diagnosis with similar conditions such as acute fatty liver of pregnancy, haemolytic-uraemic syndrome or thrombotic thrombocytopenic purpura, which imply different approaches.

■ CASE REPORT

The patient was a previously healthy 33 year-old black woman, with two previous complication-free pregnancies, presenting at 32 weeks of an otherwise uneventful pregnancy, with sudden onset severe midepigastic pain and hypertension (190-90mmHg). She denied alcohol, drug or medication abuse, fever or previous hepatitis. On examination, the patient

remained alert and the neurology assessment was normal. The sclera revealed mild icterus, with no skin lesions or oedema. Heart and lung examination were normal and the abdominal distension was consistent with a *gravid* uterus. Laboratory tests showed microangiopathic haemolytic anaemia (haemoglobin dropped from 13.2g/dl to 7.1g/ the first day, LDH 4054 IU/l and schistocytes on blood smear), elevated liver enzymes (AST 4452 and ALT 3910 IU/l), total bilirubin of 2.8mg/dl and low platelet count ($50 \times 10^9/l$) (Figures 1 and 2). The urinalysis revealed proteinuria (258 mg/dl) and was otherwise normal.

Due to a preterm gestation with no favourable cervix she was submitted to an emergency caesarean section (4 hours after admission), without major immediate complications for the newborn (Apgar score of 6, 9, 10 at 1, 5 and 10 minutes respectively).

The patient was admitted to our intensive care unit with suspected HELLP syndrome. She remained hypertensive the following day with oliguria unresponsive to high dose furosemide perfusion (12mg/h). She also had transient coagulation disorders (APTT 39/29sec, PT 19.2/11sec, D-Dimers 2098ng/ml and low fibrinogen (176mg/dl)) that resolved without the need for fresh frozen plasma infusion. The antiphospholipid antibodies were negative. Abdominal CT scan showed moderate hepatic steatosis without any other hepatic complications such as Glisson's capsule haematoma.

On admission she immediately began dexamethasone (10mg every 12 hours), antihypertensive therapy with intravenous sodium nitroprusside ($6 \mu\text{g/Kg/min}$) and red blood cell transfusion (two units of packed red blood cells). On the 3rd day, due to maintained oliguria ($<200 \text{ ml}/24\text{h}$), elevated serum creatinine 5.1 mg/dl and urea 140 mg/dl, haemodiafiltration was initiated, as there was no other technique available in the intensive care unit. She required continuous renal replacement therapy for 6 days, with gradual and complete recovery of the haemogram, hepatic and renal function over the following 5 days.

DISCUSSION

HELLP syndrome typically develops in the third trimester of pregnancy and occurs in 3 to 12% of patients with pre-eclampsia². This relationship remains controversial, with some authors considering them as separate disorders, in that as many as 15 to 20% of patients do not have previous hypertension. The aetiology is not completely known and it may, at least in part, be caused by placenta-derived proteins such as CD95⁴. These apoptotic proteins can cause hepatic and endothelial cell damage, leading to a pathogenic process associated with platelet consumption and thrombotic microangiopathy, resulting in acute tubular necrosis with oliguria and proteinuria³.

Laboratory evolution (AST, ALT, LDH)

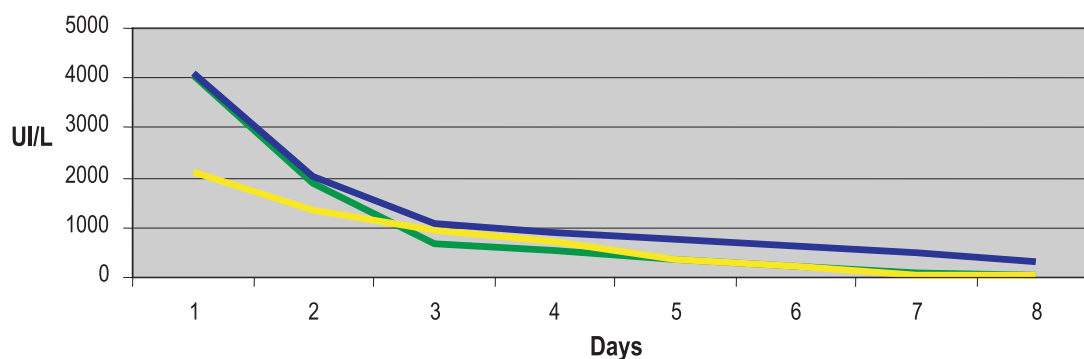


Figure 1

Evolution of serum AST, ALT and LDH concentrations

Platelet count evolution

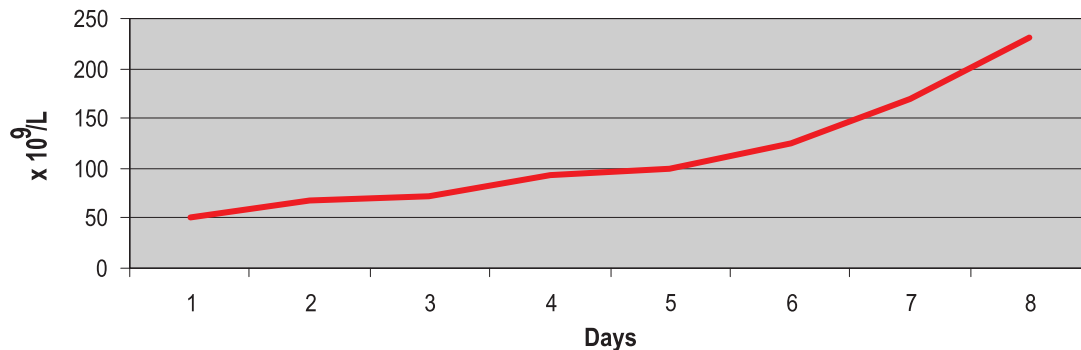


Figure 2

Platelet count evolution

The clinical picture includes abdominal pain and tenderness, nausea, malaise and sometimes jaundice. Hypertension and proteinuria are present in approximately 85% of cases¹.

The diagnosis is based upon characteristic laboratory findings: microangiopathic haemolytic anaemia with schistocytes in the blood smear, platelet count $<100 \times 10^9/L$, serum lactate dehydrogenase >600 IU/l or total bilirubin level >1.2 mg/dl and serum aspartate aminotransferase >70 IU/l.

Usually the liver is the primary organ involved and, in severe cases, haematomas can develop in the subcapsular area, contributing to hepatic necrosis. Abdominal ultrasound or CT scan are needed to exclude these complications, especially if the serum liver enzyme values are very high.

Some degree of acute renal failure (ARF) can be seen in about 8% of patients with HELLP syndrome^{4,5}, but creatinine levels above 4 mg/dl, requiring renal replacement therapy, as in this case, are much rarer^{2,3}. When ARF follows HELLP syndrome there is an increased risk of maternal mortality (9.6% in one series)¹, but women with previously normal kidney function who develop ARF as part of an obstetric complication usually completely recover renal function.

HELLP syndrome may occasionally be confused with other conditions complicating pregnancy,

especially in the spectrum of diseases presenting with microangiopathic haemolytic anaemia, thrombocytopenia and different degrees of renal and hepatic involvement. These include acute fatty liver of pregnancy, haemolytic-uraemic syndrome (HUS) or thrombotic thrombocytopenic purpura (TTP), with different treatment and outcomes. Acute fatty liver of pregnancy is an obstetric emergency that may become fulminant hepatic failure. The aetiology is unknown but it may be associated to a familial metabolic defect of fatty acid metabolism. Here, ARF occurs in 90% of cases⁶ and may resemble hepatorenal syndrome with a low fractional sodium excretion and a benign sediment. Treatment includes inducing delivery and supportive measures.

HUS is typically observed in infants and children, usually associated with prodromal diarrhoea, but most adult patients are women either on oral contraceptives, or with peri- or postpartum obstetric complications. HUS and TTP are probably best classified as part of a spectrum of HUS-TTP disorders. The pathogenesis of the two diseases is probably similar and with the involvement of a plasma circulating platelet-agglutination factor. In TTP the hyaline micro thrombi occur throughout the microcirculation of the brain, skin, gut, skeletal muscles, spleen, adrenals and heart, while in HUS the micro thrombi are essentially confined to the kidneys. Some distinctive features of HELLP syndrome and HUS/TTP

include coagulation abnormalities in the first and isolated platelet consumption in the second. Furthermore, HUS/TTP is not generally improved by termination of pregnancy.

The distinction of these different entities is important since HELLP syndrome usually resolves with supportive care following delivery and HUS/TTP is generally irreversible without plasma exchange.

The use of corticosteroids in HELLP syndrome, as in the case described, for their potential effect on an inflammatory component of the disease is still a matter of discussion⁷. Some studies have showed a more rapid improvement in laboratory and clinical parameters, especially in HELLP syndrome with a platelet count $<50 \times 10^9/l$, but all were small or had some design limitation^{2,4,8}. Two recent meta-analyses have summarised the available data and showed no benefit to the use of corticosteroids^{9,10}.

There has been recent speculation that antiphospholipid syndrome is associated with HELLP syndrome as well as TTP and HUS. Some authors also classify those syndromes as microangiopathic antiphospholipid syndromes (MAS) when they occur in a patient with antiphospholipid antibodies and there is no large vessel abnormalities¹¹. How antiphospholipid antibodies give rise to those syndromes is still a matter for further research.

In summary, ARF with renal replacement therapy is a rare complication of HELLP syndrome and requires differential diagnosis with other similar entities. Early diagnosis is critical because morbidity and mortality associated with the syndrome have been reported to be as high as 25%^{12,13}. The outcome is generally good when management is in a specialised centre, and includes continuous monitoring during labour, prompt delivery and supportive therapy. Administration of dialysis or medication must take into account the effect on both the mother and the foetus.

Conflict of interest statement. None declared.

References

- Sibai BM, Ramadan MK, Usta I, Salama M, Mercer BM, Friedman SA. Maternal morbidity and mortality in 442 pregnancies with hemolysis, elevated liver enzymes, and low platelets (HELLP syndrome). *Am J Obstet Gynecol* 1993;169:1000-6
- Malvino E, Muñoz M, Ceccotti C, et al. [Maternal morbidity and perinatal mortality in HELLP syndrome. Multicentric studies in intensive care units in Buenos Aires area]. *Medicina (B Aires)* 2005;65:17-23
- Martínez de Ita AL, García Cáceres E, Helguera Martínez AM, Cejudo Carranza E. [Acute renal insufficiency in HELLP syndrome]. *Ginecología y obstetricia de México* 1998;66:462-8
- Martin JN, Rose CH, Briery CM. Understanding and managing HELLP syndrome: the integral role of aggressive glucocorticoids for mother and child. *Am J Obstet Gynecol* 2006;195:914-34
- Selçuk NY, Odabas AR, Cetinkaya R, Tonbul HZ, San A. Outcome of pregnancies with HELLP syndrome complicated by acute renal failure (1989-1999). *Renal failure* 2000;22:319-27
- Bernau J, Degott C, Nouel O, Rueff B, Benhamou JP. Non-fatal acute fatty liver of pregnancy. *Gut* 1983;24:340-4
- Van Runnard Heimel PJ, Franx A, Schobben AF, Huisjes AJ, Derks JB, Bruinse HW. Corticosteroids, pregnancy, and HELLP syndrome: a review. *Obstetrical & gynecological survey* 2005;60:57-70; quiz 3-4
- O'Brien JM, Shumate SA, Satchwell SL, Milligan DA, Barton JR. Maternal benefit of corticosteroid therapy in patients with HELLP (hemolysis, elevated liver enzymes, and low platelet count) syndrome: impact on the rate of regional anesthesia. *Am J Obstet Gynecol* 2002;186:475-9
- Matchaba P, Moodley J. Corticosteroids for HELLP syndrome in pregnancy. *Cochrane database of systematic reviews (Online)* 2004;CD002076
- Vidaeff AC, Yeomans ER. Corticosteroids for the syndrome of hemolysis, elevated liver enzymes, and low platelets (HELLP): what evidence? *Minerva ginecologica* 2007;59:183-90
- Asherson RA. New subsets of the antiphospholipid syndrome in 2006: "PRE-APS" (probable APS) and microangiopathic antiphospholipid syndromes ("MAPS"). *Autoimmunity reviews* 2006; 6:76-80
- Osmanagaoglu MA, Osmanagaoglu S, Ulusoy H, Bozkaya H. Maternal outcome in HELLP syndrome requiring intensive care management in a Turkish hospital. *São Paulo medical journal, Revista paulista de medicina* 2006;124:85-9
- Drakeley AJ, Le Roux PA, Anthony J, Penny J. Acute renal failure complicating severe preeclampsia requiring admission to an obstetric intensive care unit. *Am J Obstet Gynecol* 2002;186:253-6

Correspondence to:

Dr Ana T. Boquinhas
Serviço de Medicina I
Hospital Egas Moniz
Centro Hospitalar de Lisboa Ocidental
Rua da Junqueira, 126
1349-019 Lisboa, Portugal
E-mail: a.boquinhas@gmail.com