

Persistent left superior vena cava

Fátima Silva¹, Nuno Oliveira¹, Carla Lima¹, António Ramires¹, Fátima Costa¹, Vítor Matos², Armando Carreira¹

¹Department of Nephrology and ²Department of Cardiology
Centro Hospitalar de Coimbra. Coimbra, Portugal.

Received for publication: 05/08/2007

Accepted in revised form: 06/12/2007

ABSTRACT

Persistence of the left superior vena cava is the most common anatomic variant of thoracic venous circulation. This anomaly results from the persistence of the left anterior cardinal vein. A persistent left superior vena cava usually drains into the right atrium by way of a dilated coronary sinus. It may complicate the placement of central vein catheters in the jugular and subclavian veins and, as such, nephrologists should be aware of the existence of this anatomic variant. Here we describe an adult patient with persistence of the left superior vena cava identified during placement of a haemodialysis central venous catheter and briefly review the literature on the subject.

Key-Words:

Congenital anomaly; haemodialysis; persistent left superior vena cava.

PLSVC occurs in 0.3% to 0.5% of the general population²⁻⁴. In patients with congenital heart disease (particularly atrial septal defects, cor triatrium and mitral atresia) its prevalence is higher, between 2% and 4.4%⁵. It is worth noting that in this population there is an increased risk of stroke and even cerebral abscesses related to the endovenous manipulation of the left arm⁶. More commonly PLSVC is just a variant of the normal anatomy with no associated symptoms or signs. Chest X-ray and electrocardiogram do not show significant changes⁷. The diagnosis is usually incidental during echocardiogram, chest-CT or chest-MRI performed for some other reason or during invasive procedures such as placement of a central venous catheter^{8,9}.

As the right internal jugular vein is arguably the optimal location for placement of a haemodialysis catheter, nephrologists should be aware of the existence of this anatomic variant.

INTRODUCTION

Persistence of the left superior vena cava (PLSVC) is the most common anatomic variant of venous thoracic circulation. It results from the abnormally persistent patency of the left anterior cardinal vein, which is usually present during the early embryological developmental period, and the obliteration of the common cardinal and proximal part of the anterior cardinal veins on the right¹. In such cases, the blood from the right is channelled towards the left through the brachiocephalic vein. The left superior vena cava drains into the right atrium by way of an enlarged coronary sinus.

CASE REPORT

A 31 year-old male patient was admitted to the Nephrology Unit with rapidly progressive renal failure with associated severe hypertension. Past medical history was irrelevant except for an episode of ureteral colic secondary to nephrolithiasis. Due to uraemic symptoms haemodialysis was started after placement of a dual lumen uncuffed catheter in the right femoral vein. All diagnostic work-up, including renal biopsy, was inconclusive as to the aetiology of the renal disease. There was no improvement of renal function and, as the patient remained on haemodialysis, the decision was made to replace the

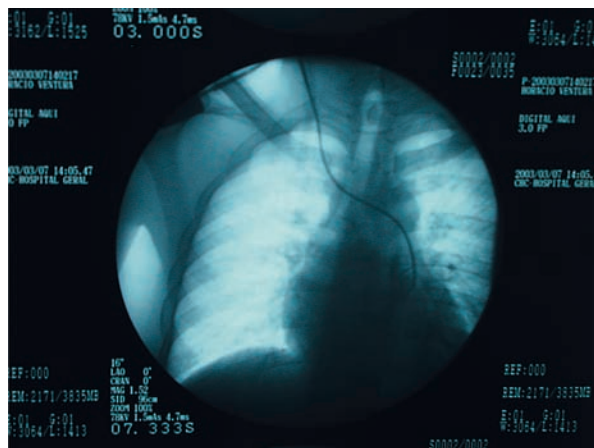


Figure 1

Angiographic view of the catheter after contrast media injection.

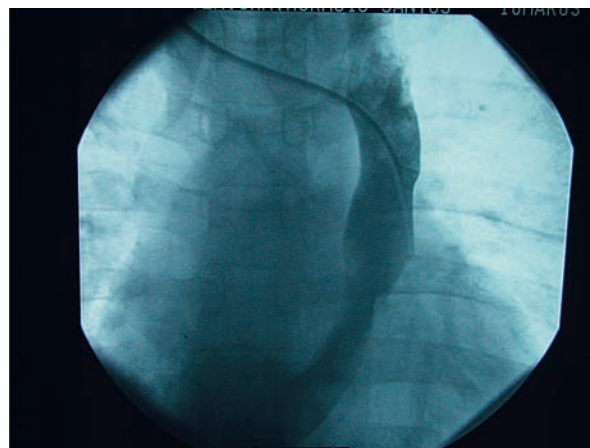


Figure 2

Angiographic view of the LSVC.

femoral catheter with another dual lumen uncuffed catheter placed in the right internal jugular vein, pending the construction of an arterio-venous fistula. The procedure was uneventful. However a control chest X-ray revealed the presence of the catheter at the left cardiac border with a median projection at the profile chest X-ray. Aspiration of both catheter ports revealed dark-red blood return and a blood gas analysis confirmed the venous placement of the catheter. An angiography was performed with injection of contrast media through the catheter (Fig. 1). The procedure revealed the presence of a left superior vena cava draining into the coronary sinus (Fig. 2). An echocardiogram performed before the placement of the catheter had shown the existence of a vascular structure, not identified in the report, adjacent to the left atrium and connected with the coronary sinus, and no other cardiac malformations. The patient was subsequently discharged and this vascular access was kept, and was used for haemodialysis for 3 months. Subsequently an arterio-venous fistula was used and the central catheter removed without any incidents. The patient is presently doing well and has been transplanted.

DISCUSSION

The PLSVC is the most frequent variant of the venous thoracic circulation. During normal embryological

development the LSVC becomes residual, and is represented at birth by a small vestigial vein adjacent to the posterior wall of the left atria (Marshall's oblique vein) and by a fibrous band attached to this vein (Marshall's ligament)¹. According to Schummer³, the superior vena cava system can be classified as type I, normal anatomy; type II, only PLSVC; type IIIa, right and left superior vena cava with connection; and type IIIb, right and left superior vena cava without connection. The most frequent variant of the normal anatomy is the simultaneous presence of both right and left cava veins (double superior vena cava, type III), although, as our patient shows, there are some reported cases of absence of the right vena cava, type II. Although the LSVC usually drains into the right atria by way of the coronary sinus, the drainage is sometimes made into the left atria (because of partial or complete absence of the roof of the coronary sinus) thereby producing a right-left shunt⁸.

Although more commonly asymptomatic, PLSVC, with or without coronary sinus dilation, may be associated with cardiac electric impulse conducting defects, conduction bypass tracts and therefore with increased risk of reentrant tachycardia⁹.

Haemodialysis through a catheter placed at the LSVC is possible, as was demonstrated by our patient and was reported in the literature in similar cases without intercurrents^{5,10,11}.

Conclusion: PLSVC is not at all an infrequent variant of the normal anatomy and it may complicate the insertion of central venous catheters in the jugular and subclavian veins, especially on the left side. It may raise doubts as to the location of the catheter, so clinicians should be aware that PLSVC exists in order to avoid misinterpretation of control X-ray and prevent unnecessary removal of properly placed catheters.

Conflict of interest statement. None declared.

References

- ¹ Sadler TW. Langman's medical embryology, 7th ed. Williams and Wilkins, Baltimore, 1995:212-224
- ² Sarodia BD, Stoller JK. Persistent left superior vena cava: Case report and literature review. *Respir Care* 2000;45:411-6
- ³ Schummer W, Schummer C, Frober R. Persistent left superior vena cava and central venous catheter position: clinical impact illustrated by four cases. *Surg Radiol Anat* 2003;25:315-21
- ⁴ Campbell M, Deuchai DC. The left sided superior vena cava. *Bethcart J* 1954;16:423-33
- ⁵ Prada FJ, Forteza F, Morey MA, *et al.* Persistencia de la Vena Cava Superior Izquierda descubierta durante la implantacion de catéter para hemodiálisis. *Nefrología* 2002; vol XXII, nº 2
- ⁶ Kao CL, Chang JP. Malposition of a catheter in the persistent left superior vena cava a rare complication of totally implantable devices. *J Cardiovascular Surg* 2003;44:145-7
- ⁷ Fabio Miraldi, Cira Di Gioia, Piero Proietti, *et al.* Cardinal vein isomerism – An embryological hypothesis to explain a persistent left superior vena cava draining into the roof of the left atrium in the absence of coronary sinus and atrial septal defect. *Cardiovascular Pathology* 2002;11:149-152
- ⁸ Tahir Tak, Eron Crouch, Glen B. Drake. Persistent left superior vena cava: incidence, significance and clinical correlates. *Intern J Cardiol* 2002;82:91-93
- ⁹ Weiss C, Cappato R, Willenas S, *et al.* Prospective evaluation of the coronary sinus anatomy in patients undergoing electrophysiologic study. *Clin Cardiol* 1999;22:537-43
- ¹⁰ Kuppasamy TS, Balogun RA. Unusual Placement of a Dialysis Catheter: Persistent Left Superior Vena Cava. *Am J Kidney Dis* 2004;43:365-367
- ¹¹ Kim Choi, Jean HK, Han CH, *et al.* Persistent left superior vena cava detected by hemodialysis catheterization. *Nephron* 1999;83:87-8

Correspondence to:

Dr Nuno Oliveira
Rua Flávio Rodrigues, 53 - 4º Esq
3030 Coimbra, Portugal
Email: nunomacoliveira@gmail.com