

Indinavir nephropathy: A reversible cause of progressive renal disease

Carlos Lucas¹, Margarida Gonçalves¹, Ana P. Martins², Maria J. Pais¹

¹ Department of Nephrology and ² Department of Histopathology.
Hospital de Santa Cruz, Carnaxide, Portugal.

Received for publication: 21/01/2007

Accepted in revised form: 15/05/2007

ABSTRACT

Renal dysfunction is a common occurrence in human immunodeficiency virus (HIV) infected individuals. It is frequently caused by the administration of drugs with nephrotoxic potential. The addition of protease inhibitors to the anti-retroviral regimen of HIV-infected patients was a significant advance, reducing morbidity and mortality in that population. Indinavir is one of the most widely used protease inhibitors and while it is generally well tolerated and safe, its use has been associated with a spectrum of crystal-induced renal conditions, including asymptomatic crystalluria, nephrolithiasis and crystal-induced acute renal failure and less frequently with the insidious tubulointerstitial lesion indinavir nephropathy.

The authors report a case of an HIV-infected 45-year-old female treated with indinavir for two years with slowly rising serum creatinine levels, microscopic haematuria and low-grade proteinuria. Renal biopsy revealed low degree interstitial fibrosis and tubular dilation with needle-shaped crystals within their lumina and associated giant cell formation. After the switch from indinavir to nelfinavir the estimated glomerular filtration rate rose from 17 to 40 ml/min/1.73m² over several months.

The authors discuss the risk factors involved as well as the pathogenesis and potential preventive measures of this apparently reversible cause of progressive renal deterioration in the HIV-infected population.

Key-Words:

Chronic kidney disease; human immunodeficiency virus; indinavir; tubulointerstitial nephropathy.

INTRODUCTION

The development of antiretroviral drug regimens containing protease inhibitors has been a substantial advance in the treatment of HIV infection^{1,2}. Indinavir is one of the most widely prescribed protease inhibitors and has been since its introduction into clinical practice a well known cause of nephrolithiasis and crystal-induced acute renal failure³⁻⁶. More recently, the drug was also associated with the development of a slowly progressive tubulointerstitial lesion called indinavir nephropathy⁷. We report a case of an HIV-infected patient who developed a progressive rise in serum creatinine levels after two years of indinavir therapy. Renal biopsy revealed a tubulointerstitial lesion compatible with indinavir nephropathy. We discuss possible risk factors involved, pathogenesis and preventive measures.

CLINICAL REPORT

A 45-year-old black female was referred to our renal clinic due to a rising serum creatinine over the previous few months. The past medical history was unremarkable until five years ago, when she was found to be seropositive for HIV-2. She was then placed on

an anti-retroviral regimen consisting of Zidovudine (AZT) and Lamivudine (3TC) with poor virological control in the following years. Indinavir and ritonavir were added to this regimen two years prior to our evaluation and serum creatinine was 1.1 mg/dl at the time. Under quadruple therapy the viral load became undetectable, the CD4 count remained stable around 200/ μ L, and there were no opportunistic infections. Seven months previously, the serum creatinine had been elevated (1.9 mg/dl) and when the patient was seen for the first time in our clinic her serum creatinine was 2.7 mg/dl with a estimated glomerular filtration rate of 17 ml/min/1.73m². During that period there was no history of opportunistic infections, non-steroidal anti-inflammatory drug use, arterial hypertension, diabetes mellitus, rash, arthralgias or symptomatic nephrolithiasis. Medications included Zidovudine (AZT) 250 mg twice daily; Lamivudine (3TC) 150 mg daily; Indinavir 800 mg every 12 hours; Ritonavir 100 mg every 12 hours; Co-trimoxazole 960 mg daily and Lorazepam 1mg at bedtime.

Physical examination showed an undernourished patient with a body mass index (BMI) of 17.3. Blood pressure was 120/70 mmHg with a pulse of 83 beats/min. Examination of the head, neck, chest, abdomen and extremities was unremarkable.

The patient presented a normochromic and normocytic anaemia with a haemoglobin value of 10.2 mg/dl. The serum urea and creatinine values were 78 mg/dl and 2.7 mg/dl respectively. Urinary dipstick analysis was positive for protein and microscopy revealed over 20 red blood cells per high power field without crystals. A 24-hour urine collection revealed 450 mg of protein.

Serum protein electrophoresis showed a polyclonal hypergammaglobulinemia without monoclonal spikes. The anti-nuclear antibody assay was negative as were the anti-DNA, ANCA and rheumatoid factor assays. The patient was negative for the hepatitis B virus surface antigen (HBsAg) and there were no antibodies against the hepatitis C virus. The HIV viral load was undetectable and the CD4 count was 200/ μ L.

Ultrasound examination of the kidneys showed a right kidney of 8 cm and a left kidney of 7.7cm. The cortices were slightly echogenic and there was no evidence of nephrolithiasis or hydronephrosis.

A percutaneous renal biopsy was performed to establish a definitive diagnosis.

■ Biopsy findings

The biopsy contained mainly renal medulla. The 8 glomeruli seen showed no morphological abnormalities. Some of the tubules were dilated and contained elongated needle-shaped crystals in their lumina which were surrounded by multinucleated giant cells. There were a small degree of interstitial fibrosis and tubular atrophy. Congo red staining was negative.

Immunofluorescence revealed a low degree deposition of C3 and IgM in the mesangium and was negative for IgG, IgA, C1, C4 and fibrinogen.

■ Clinical course

A diagnosis of indinavir nephropathy was made and the offending drug replaced by nelfinavir. At a follow-up visit 5 months after the renal biopsy, the serum creatinine was 1.4 mg/dl, the physical examination remained negative and the creatinine clearance rose to 40 ml/min/1.73 m².

■ DISCUSSION

Since the inclusion of indinavir in the armamentarium of anti-retroviral drugs, its association with the frequent occurrence of renal calculi has been well appreciated. The initial product monograph reported an incidence of urinary calculi of approximately 4%^{3,4}. However, subsequent research demonstrated that incidence of nephrolithiasis was much higher, rising to 43.2% in some studies⁸. The basic factor in the pathogenesis of indinavir nephrolithiasis is the reduced solubility of indinavir at urine pH > 5.5⁹. Indinavir crystallises as very large needle-shaped crystals which form large plates or radiating aggregates. Such crystals easily obstruct the renal tubules and form urinary calculi⁹.

Indinavir therapy was also associated with the occurrence of reversible acute renal failure related to crystal formation and interstitial nephritis; the renal failure usually reversible after indinavir withdrawal¹⁰⁻¹².

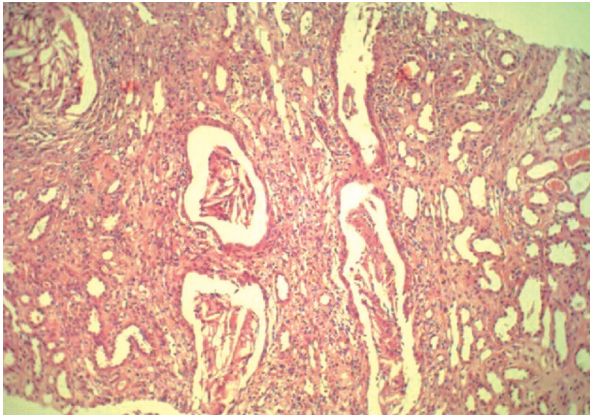


Figure 1

H&E; x100. Mild to moderate interstitial fibrosis, tubular atrophy with crystals in the lumen.

In contrast to urinary calculi and acute renal failure, a form of slowly progressive renal failure related to long-term treatment with indinavir was described for the first time in 1997 by Tashima *et al* 7. The renal biopsy specimen revealed interstitial fibrosis and tubular atrophy and the collecting ducts contained crystals surrounded by giant cells. In that case report, discontinuing the offending drug resulted in a decrease of the serum creatinine levels⁷.

Since that first report, there have been several additional reports of patients with a slowly progressive increase in serum creatinine levels while on long-term therapy with indinavir¹³⁻¹⁸ and the condition has been named indinavir nephropathy.

From these reports a clinical and pathological pattern becomes evident. Patients with indinavir nephropathy develop a slow, progressive and usually asymptomatic rise in serum creatinine which may or may not be associated with new-onset arterial hypertension. The urinalysis shows microhaematuria, low-grade proteinuria and sometimes pyuria and eosinophiluria. Hystopathological analysis reveals predominantly tubulointerstitial changes with fibrosis, tubular atrophy and crystals within the tubules sometimes surrounded by histiocytes and giant cells. Glomeruli are usually normal.

The indinavir nephropathy incidence in HIV-patients is probably higher than previously assumed and has been reported to be as high as 18% in some studies^{19, 20}.

One important point regarding indinavir nephropathy is the degree of reversibility of the condition after discontinuation of the offending drug. Most reports show that the rise in serum creatinine returns to baseline on discontinuation of indinavir, suggesting that the tubulointerstitial injury it causes is, in most cases, reversible. However that is not always the case, and although the discontinuation of indinavir does improve renal function in the vast majority of cases, in the presence of significant renal atrophy ascertained by renal ultrasound the serum creatinine levels do not usually return to baseline values^{21,22}. In the present case, kidney function improved substantially at a fairly advanced stage of kidney failure despite the structural changes observed by ultrasound sonography. However, the patient had a very low BMI and the degree of renal atrophy ascertained by sonography was likely overestimated.

It remains unknown whether this pattern of injury is related to tubular obstruction with crystals or a cell-mediated immune process, although it is probably caused by a combination of the two¹⁸. Assuming that the intratubular precipitation of crystals plays an important role, at least in susceptible individuals, one might consider that the risk profile for the development of indinavir nephropathy is similar to the one documented for indinavir nephrolithiasis. This means the patients at higher risk are those with higher circulating levels of the drug or with smaller urine volumes¹⁸. This would include patients with chronic diarrhoea²³, episodes of dehydration brought on by elevated temperatures²⁴, co-infection with hepatitis B or C virus which can result in reduced hepatic indinavir catabolism and increased renal excretion²⁵, patients taking cytochrome P450III inhibitors (clarithromycin, ketoconazole)²⁶ and use of standard posology in patients with low body mass,²⁷ as was the case with our patient. Concomitant administration of drugs known to cause crystalluria such as acyclovir^{21,28} and sulfamethoxazole^{19,29} also increase the risk of developing indinavir nephropathy. Sulfamethoxazole crystals may act as a nidus for indinavir crystallisation¹⁸.

Preventive measures to reduce the likelihood of renal dysfunction with indinavir therapy include a reduction of the dose in patients with risk factors and an increase of the urinary volume by increasing the fluid intake. This can be achieved by the ingestion of at least 150 ml of fluid when taking the drug

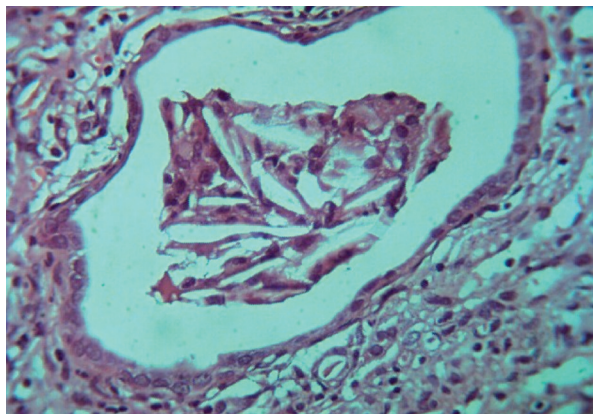


Figure 2
H&E; x400. Detail of a renal tubule with elongated needle-shaped crystals in the lumen.

and every hour for two hours afterwards³⁰. However, it has been shown that patients on indinavir seldom increase their fluid intake despite instructions to do so. In the study by Gagnon *et al.* urinary specific gravity remained the same before and after the initiation of indinavir, despite repeated instructions to increase fluid intake³¹.

Same data suggests that the use of pharmacokinetically guided dose reductions may safely maintain patients on an indinavir-containing regimen even when there is established nephrotoxicity³². However, and until further data is available, the immediate discontinuation of the drug is recommended in patients with indinavir nephropathy.

CONCLUSION

Indinavir nephropathy is a clinical and pathological entity characterised by a slowly progressive rise in serum creatinine in an asymptomatic HIV-patient on long-term therapy with indinavir. The renal biopsy typically reveals tubulo-interstitial injury, often associated with tubular crystal deposition and giant cell formation. Clinical risk factors appear to be similar to the ones associated with indinavir crystalluria and nephrolithiasis and they either cause elevated circulating levels of the drug and/or reduce urinary volumes. This condition becomes important in the differential diagnosis of renal dysfunction in HIV-infected patients not only because its incidence is

probably higher than previously thought but also because it represents a usually reversible cause of renal deterioration in this population.

Conflict of interest statement. None declared.

References

- ¹Bartlett JG. Protease inhibitors for HIV infection (Editorial). *Ann Intern Med* 1996; 124:1086-1088
- ²Deeks SG, Smith M, Holodny M, Kahn JO. HIV-1 protease inhibitors. A review for clinicians. *JAMA* 1997;277:145-153
- ³Merck & Co. Crixivan (indinavir sulphate) [Product monograph]. West Point (PA): Merck & Co., 1997.
- ⁴European Agency for the Evaluation of Medicinal Products. Commission decision of 4 October 1996 granting the marketing authorization for the medicinal product for human use, "CRIXIVAN® - Indinavir". London: European Agency for the Evaluation of Medicinal Products, 1996.
- ⁵Daudon M, Estepa L, Viard JP, Joy D, Jungers P. Urinary stones in HIV-1 positive patients treated with indinavir. *Lancet* 1997;349:1294-1295
- ⁶Kopp JB, Miller KD, Mican JA, *et al.* Crystalluria and urinary tract abnormalities associated with indinavir. *Ann Intern med* 1997;127:119-125
- ⁷Tashima KT, Horowitz JD, Rosen S: Indinavir nephropathy. *N Engl J Med* 1997; 336:138-140
- ⁸Saltel E, Angel JB, Futter NG, Walsh WG, O'Rourke K, Mahoney JE. Increased prevalence and analysis of risk factors for indinavir nephrolithiasis. *J Urol* 2000;164:1895-1897
- ⁹Servais A, Daudon M, Knebelman B. Drug-induced renal calculi. *Ann Urol* 2006; 40:57-68
- ¹⁰Berns JS, Cohen RM, Silverman M, Turner J. Acute renal failure due to indinavir crystalluria and nephrolithiasis: report of two cases. *Am J kidney Dis* 1997;30:558-560
- ¹¹Jaradat M, Phillips C, Yum MN, Cushing H, Moe S. Acute tubulointerstitial nephritis attributable to indinavir therapy [letter]. *Am J Kidney Dis* 2000; 35:E16
- ¹²Anglicheau D, Duvic C, Nedelec G. Sudden anuria due to indinavir crystalluria. *Nephron* 2000;86:364-365
- ¹³Perazella MA, Kashgarian M, Cooney E. Indinavir nephropathy in an AIDS patient with renal insufficiency and pyuria. *Clin Nephrol* 1998;50:194-196
- ¹⁴Chen SC, Nankivell BJ, Dwyer DE. Indinavir-induced renal failure. *AIDS* 1998;12:440-441
- ¹⁵Martinez F, Mommeja-Marin H, Estepa-Maurice L, *et al.* Indinavir crystal deposits associated with tubulointerstitial nephropathy. *Nephrol Dial Transplant* 1998;13:750-753
- ¹⁶Sarletti M, Petter A, Zangerle R. Indinavir and interstitial nephritis. *Ann Intern Med* 1998;128:320-321
- ¹⁷Grabe DW, Eisele G, Miller C, Singh J, Stein D. Indinavir-induced nephropathy. *Clin Nephrol* 1999;51:181-183
- ¹⁸Reilly RF, Kory T, Perazella MA. Indinavir nephropathy revisited: A pattern of insidious renal failure with identifiable risk factors. *Am J Kidney Dis* 2001;38:E23
- ¹⁹Boubaker K, Sudre P, Bally F, *et al.* Changes in renal function associated with indinavir. *AIDS* 1998;12:249-254

- ²⁰Sarcelletti M, Petter A, Romani N, *et al.* Pyuria in patients treated with indinavir is associated with renal dysfunction. *Clin Nephrol* 2000;54:261-270
- ²¹Hanabusa H, Tagami H, Hataya H. Renal atrophy associated with long-term treatment with indinavir. *N Engl J Med* 1999;340:392-393
- ²²Cattelan AM, trevenzoli M, naso A, Meneghetti R, Cadrobbi P. Severe hypertension and renal atrophy associated with indinavir. *Clin Infect Dis* 2000;30:619-621
- ²³Famularo G, Di Toro S, Moretti S, De Simone C. Symptomatic crystalluria associated with indinavir. *Ann Pharmacother* 2000;34:1414-1418
- ²⁴Martinez E, Leguizamon M, Mallolas J, Miro JM, Gatell JM. Influence of environmental temperature on incidence of indinavir-related nephrolithiasis. *Clin Infect Dis* 1999;29:422-425
- ²⁵Malavaud B, Dinh B, Bonnet E, Izopet J, Payen JL, Marchou B. Increased incidence of indinavir nephrolithiasis in patients with hepatitis B or C virus infection. *Antivir Ther* 2000;5:3-5
- ²⁶Dieleman JP, Sturkenboom MC, Jambroes M, *et al.* Risk factors for urological symptoms in a cohort of users of the protease inhibitor indinavir sulphate: the ATENA cohort. *Arch Inter Med* 2002;162:1493-1501
- ²⁷Meraviglia P, Angeli E, Del Sorbo F, *et al.* Risk factors for indinavir related renal colic in HIV patients: predictive value of indinavir dose/body mass index. *AIDS* 2002;16:2089-2093
- ²⁸Herman JS, Ives NJ, Nelson M, Gazzard BG, Easterbrook PJ. Incidence and risk factors for the development of indinavir-associated renal complications. *J Antimicrob Chemother* 2001;48:355-360
- ²⁹de Araujo M, Seguro AC. Trimethoprim-sulphamethoxazole (TMP/SMX) potentiates indinavir nephrotoxicity. *Antivir Ther* 2002;7:181-184
- ³⁰Daudon M, Estepa L, Viard JP, Joly D, Jungers P. Urinary stones in HIV-1 positive patients treated with indinavir. *Lancet* 1997;349:1294-1295
- ³¹Gagnon RF, Tecimer SN, Watters AK, Tsoukas CM. Prospective study of urinalysis abnormalities in HIV-positive individuals treated with indinavir. *Am J Kidney Dis* 2000; 36:507-515
- ³²Boyd MA, Siangphoe U, Ruxrungtham K, *et al.* The use of pharmacokinetically guided indinavir dose reductions in the management of indinavir-associated renal toxicity. *J Antimicrob Chemother* 2006;57:1161-1167

Correspondence to:

Dr Carlos Lucas
 Department of Nephrology
 Hospital de Santa Cruz
 Avenida Prof. Reynaldo dos Santos
 2790-134 CARNAXIDE
 PORTUGAL
 E-mail: Cortezlucas@netcabo.pt