

Ultrasound in vascular access management – How to start and enhance a comprehensive program

Tiago Assis Pereira

Nephrology Department, Hospital Curry Cabral, Centro Hospitalar Lisboa Central, Lisbon, Portugal

INTRODUCTION

Diagnostic medicine has evolved from a solely physical examination to a setting where a diversity of complementary diagnostic methods is applied. Subsequently, most diagnosis and therapeutics are performed after appropriate exams confirming the clinical suspicion.

Similarly, vascular access (VA) creation and monitoring has been revolutionized by ultrasound (US) implementation, thereby supplanting physical examination and sparing angiographic/surgical interventions through 1) deciding the location of VA creation, 2) diagnosing dysfunctional VA and 3) establishing if a vascular lesion needs to be corrected (vs conservative management).

This article presents the author's perspective of a VA ultrasound program, after its implementation and expansion in the Nephrology Department of Hospital Curry Cabral. The programme was founded in mid-2017 as an external consultation, and then enhanced to give support to hospitalized patients (dialysis or pre-dialysis patients admitted for or with vascular issues). A total of 330 vascular mapping and 278 VA ultrasound evaluations were performed by December 2020.

ROLE OF ULTRASOUND MAPPING FOR VASCULAR ACCESS CREATION

After an appropriate history and physical examination, preoperative vascular mapping by US should be the next step in vascular access creation.

At first, it was advocated only for patients with previous multiple or failed access creation, inconclusive physical exam or sociodemographic and clinical risk factors for VA failure. Thereafter, its utilization has been increasingly extended and in some centers a model of universal evaluation has been adopted.

Not all studies were concordant as to US superiority against physical examination, and international guidelines and area specialists still disagree on its performance on a **universal basis**, a position strongly defended by the Spanish clinical guidelines. Either way, together with clinical findings (history and physical exam) ultrasound information should enable an integrative and structured surgical decision.^{1,2}

Yet, ultrasound's non-invasive nature and the avoidance of unnecessary surgeries resulting in mal-functioning or mal-functioning VA are benefits to be considered. The latter, ultimately, leads to the need

of a central venous catheter for dialysis initiation and discourages patients for future surgeries.

ROLE OF ULTRASOUND FOR VASCULAR ACCESS EVALUATION

The purpose of VA evaluation is to determine if VA is normally functioning, to reduce the risk of thrombosis and ultimately improve survival.¹⁻³

VA physical exam and, if the patient is already on dialysis, its cannulation, hemostasis difficulty, dialysis efficiency, and vascular pressure determinations can indicate VA dysfunction and the need for evaluation. However, these features are erratic and difficult to interpret, as each one depends on many variables (cannulation technique, other determinants of dialysis efficacy such as dialyzer and needle sizes, for example).

More recently, access flow (Qa) availability has incremented the efficiency of VA surveillance. Qa measurement by dilution methods seems to be the most practical and reliable hemodynamic variable to be used, but it does not identify the underlying lesion and if it can or should be corrected. Moreover, these data cannot be used in a pre-dialysis setting, since VA is not cannulated and no noninvasive Qa measurement is available.

Second-generation methods, including US, are recommended for autologous VA surveillance; however this does not apply to prosthetic arteriovenous fistula (PAF), as they are not associated with clinical benefit.¹⁻⁴

VA guidelines have pointed out that when 1) low or significant Qa reductions are detected or if 2) poor maturation, patients should be referred to an image method, from which US is considered the first-line method (if performed by an experienced clinician). Angiographic evaluation should be the next step if inconclusive exam or hemodynamically significant lesion.¹⁻³

Another US function that is widely recommended is guidance in real-time VA cannulation, as it results in less complications and more efficient dialysis.¹⁻³

Overall, VA management can be optimized by US, since it combines anatomical and hemodynamic characterization, if the patient is on dialysis or not. It should be highlighted that Qa measurement is comparable between ultrasound and dilution methods.⁵

Joining the data gathered by this method and other clinical and semiological data means a more validated decision concerning VA can be performed.

No VA surveillance of pre-dialysis patients is available, making this process more challenging. As a consequence, a US evaluation is required.

STARTING AN ULTRASOUND PROGRAM IN NEPHROLOGY

Four features are required to implement a US program for VA management – 1) **knowledge** and 2) **experience** of US and dialysis, 3) **available ultrasound equipment** and 4) **time**.

The detail “dialysis” was intentionally placed, as we cannot expect radiologists or surgeons to be the decision-makers of VA

management. The nephrologist, who deals daily with dialysis treatment and VA complications, should be central in this process.

A US machine available full-time or almost full-time is essential to perform a specific and time-consuming activity like this. An automated volume flow calculation (Qa), as specified for VA evaluation, should be inserted in the pulsed wave doppler mode.

A specific weekly time should be dedicated for first consultations (vascular mapping or VA first evaluation) and subsequent ones (VA reevaluations). Ideally, in this consultation, another period should be warranted for emergencies.

There also should be availability for a prompt US evaluation as VA complications present, either at dialysis units or in-patient departments.

A METHODOICAL REPORT OF VA ULTRASOUND – WHAT TO LOOK FOR AND WHAT TO REGISTER

VASCULAR MAPPING	
Evaluate both arms for a full information of vascular patrimony	
Arterial • Radial • Cubital • Brachial	<ul style="list-style-type: none"> • Diameter • Peak systolic velocity • Waveform (triphasic, biphasic, or monophasic) • Calcification presence and severity • Brachial artery bifurcation (normal or upper; in later, do not forget to report arterial diameters at cubital fossa) • Stenosis presence and severity • Resistivity index which can be evaluated at radial artery
Venous • Use external upper compression • Forearm and arm	<ul style="list-style-type: none"> • Pathway of suitable superficial veins • Preferred sites for arteriovenous anastomosis • Diameter along the drainage veins • Distensibility and compression • Wall quality (sclerosis, partial or total thrombosis) • Depth • If no available cephalic of basilic systems, evaluate brachial vein (s) until axillary transition • If clinical suspicion or risk factor for venous central stenosis, try evaluation of axillary and subclavian veins, including respiratory phasicity • Look for subcutaneous/dermal edema and presence of significant or various collateral veins, that would indicate venous central stenosis.
Conclusion	<ul style="list-style-type: none"> • Indicate VA options for both arms and which are associated with best outcomes – prioritize autologous and distal VA and the non-dominant arm. • In case of distal arterial compromise, indicate which side presents higher risk for distal hypoperfusion ischemic syndrome.

VASCULAR ACCESS ECODOPPLER	
For stenosis identification, consider diameter reduction > 50% and peak systolic difference (2:1, compared to adjacent normal segment). Color flow mode can also be used to look for aliasing.	
Artery	<ul style="list-style-type: none"> • Diameter • Calcification presence and severity • Stenosis presence and severity • Volume flow and resistivity index measurement (distant from anastomosis and on a straight segment); if distal VA, quantify VA also on brachial artery • In upper vascular access, describe diameter and peak systolic velocity to determine if there is already hypoperfusion that would be aggravated if VA flow increases after vascular intervention • In distal ischemic hypoperfusion syndrome, evaluate arterial flow with and without compression of AV venous limb or anastomosis
Anastomosis	<ul style="list-style-type: none"> • Diameter • Stenosis presence and severity
Vein • Evaluate all the drainage system, since post-anastomotic until axillary vein, at least; if cephalic drainage, cephalic arch has to be viewed and described	<ul style="list-style-type: none"> • Diameter (including aneurysms) • Arterialization status (wall thickness and resistance to external compression) • Stenosis presence and severity • Accessory and collateral veins (report its diameter, volume flow and flow direction) • Depth • Point appropriate cannulation areas and/or avoid forbidden areas (pseudoaneurysm, for example)

VASCULAR ACCESS ECODOPPLER

For stenosis identification, consider diameter reduction > 50% and peak systolic difference (2:1, compared to adjacent normal segment). Color flow mode can also be used to look for aliasing.

Prosthesis	<ul style="list-style-type: none"> • Same as the vein section, plus • Diameter, stenosis presence and severity of arterial and venous anastomosis • Prosthesis wall complications as pseudoaneurysms, deterioration or signs of infiltration/infection
Other findings	<ul style="list-style-type: none"> • Luminal partial or total thrombus presence • Pseudoaneurysms, including arterial (accidental puncture) • Hematoma, seroma, abscess and its location and effect on vascular access • Edema, resulting from venous hypertension
Conclusion	<ul style="list-style-type: none"> • Clinical decision, discussed with attending nephrologist and angiography and surgery teams • Normal functioning access – no need for reevaluation • Presence of non-significant lesions – reevaluate later/vigilance • Presence of significant and reversible lesions – angiographic of surgical referral • Presence of significant but irreversible lesions – new vascular mapping and referral to surgery team

MAINTENANCE AND EXPANSION OF VA ULTRASOUND PROGRAMME

There are some steps that should be featured at each VA center to grant continuous high-standard care continuity taken to enhance scientific progression and divulgation:

- Continuous self-formation and results monitoring – in addition to scientific accompanying and vascular access courses, self-monitoring of individual cases by assessing construction success and survival follow-up (in case of vascular mapping) as well as angiographic or surgical results of VA referred from US evaluation (and confronting respective US findings).
- Formation of staff – it is crucial to expand the pool of staff capable of performing US to maintain current and future activity; these should include Nephrology, Surgery, and Nursing, integrated in a comprehensive formation that also includes angiographic and operating room participation.
- Results divulgation, through scientific reunions and publications, concerning not only immediate results (e.g., vascular access construction success) but also long-term survival.
- Reinforcement of efforts for a good vascular access – it should be noted that an arteriovenous access has to be more than just functioning; it should be **usable** and proportionate consistently and long-term **efficient** dialysis; considering a (bad) functioning access per se as a success can be misleading; that’s why a complete characterization of an access should be performed recurring to US, and not only by physical examination.

ENTHUSIASM ON ULTRASOUND FOR VA MANAGEMENT – RISKS AND ILLUSIONS

Once US turn out to be useful and widely implemented, it can be dangerous if exam quality (image capture, full and exhaustive evaluation) and subsequent clinical decisions are not assured. As much as more clinicians at predialysis and dialysis settings have access to US machinery and predisposition to perform this practical exam, if quality is compromised the results can be as well. Ultimately, it would lead to discrediting US and blocking its stepwise pathway to a central position in VA management.

Additionally, US is not the gold standard exam to diagnose central vascular lesions and, unlike angiography, it is not interventional. Compared to the gold standard, which is angiography, US sensibility and specificity values are not superior to 90 and 95%, respectively.¹

With respect to diagnosis or ultrasonographic characterization, US is operator-dependent and it is based on hand-technique, hemodynamic and anatomical understanding of this peculiar vascular area, and integration of semiological and dialytic data to arrive at a right decision.

PENDING DOUBTS AND RESEARCH AREAS TO EXPLORE

Acquiring knowledge, experience and changing practical paradigms are essential in VA ultrasound. As long as data is gathered and clinical challenges are presented, many doubts arise. Below, are presented some examples of particular situations, whose answer is not obvious:

Venous branching proximally to radiocephalic fistulae – When to discard this option? – Although an adequate radial artery and distal cephalic vein are available, the venous drainage is often challenging, either due to erratic paths or further divisions. These can compromise a viable segment for bipuncture or create high venous pressure due to tightened drainage.

Median basilic vein – When radiocephalic or brachiocephalic fistulas do not seem advisable, the next option would be a brachiobasilic fistula. Due to its profound and internal location, the basilic system is usually spared from venous punctures or cannulations. However, it is not the case of the median basilic vein, which can be accessed or be constitutively suboptimal. Some kind of narrowing or parietal changes (sclerosis, lesser compression) that can compromise its maturation are frequent along its trajectory. Should we try median basilic veins? Most times yes, because of the lack of other native options and a regular and tight follow-up post-construction should identify if the access needs angiographic or surgical revision.

Biphasic arterial waveform – is it to be anastomosed? – It is not rare to find biphasic waveforms in distal arteries, including in young and

low vascular burden patients. Apart from absent proximal arterial stenosis and radial acceptable diameters and SPV, experience has not been favorable (non- published data).

Prosthetic arteriovenous fistula – should we be strict about vascular diameters? – Usually, it is advisable that PAF would be anastomosed to vessels with at least 4 mm, to maintain an adequate flow and minimizing risk of anastomosis stenosis.^{1,6} However, this arterial diameter is difficult to achieve, mainly in some patients (female, diabetic, small patients) and if we were strict, it could lead to recommendation of a proximal loop prosthesis (recurring to proximal brachial artery), whose surgery is challenging and VA survival is hampered.

Stenosis due to neointimal hyperplasia vs constitutive narrowing – After diagnosing a stenosis, the morphological aspects of US can be distinct. Roughly, two types of stenosis are apparent, based on the presence /absence of luminal defect and previous inner diameter development – **neointimal hyperplasia** and simple **constitutive narrowing**. The latter corresponds to an undeveloped vascular segment (smaller diameter compared to adjacent segments and minor parietal changes). This classification can be relevant, as the nature of stenosis can be associated with different risks of recurrence and angioplasty complications (rupture), thereby changing therapeutic approaches.

Significant radial stenosis but functioning radiocephalic fistula through palmar arch and cubital development – Arterial stenosis has been increasingly recognized, and US can easily identify it, if the lesion is peripheral. One peculiar finding has been a normofunctioning fistula, yet with hemodynamically significant arterial stenosis,

but whose survival depends on palmar arch and cubital compensatory development. Necessarily arterial flow has to pass through a high resistance circuit before reaching the drainage vein. If an access is successfully and efficiently used, there is no question. But if this question is launched in a predialytic setting (and signs such as cannulation difficulties or low dialysis efficiency are not necessarily obvious)? Can we assure that arterial flow will be enough for dialysis success?

Vascular mapping and VA ultrasound in children – what is the “normal”? – When hemodialysis and AV creation are considered in pediatric patients, we should bear in mind the particular anatomic and hemodynamic differences in pediatric patients. In sum, a lower diameter, reduced arterial flow and cardiac debit are expected; differently to adults, arterial disease is less probable due to reduced vascular burden and short-time of uremia exposition. The big question is if the usual vascular parameters applied in adults should be recommended in pediatric patients. If not, what are the thresholds? Recent publications have addressed this question and analysis of morphological parameters suggests similar results to adults, but more data is needed.^{7,8}

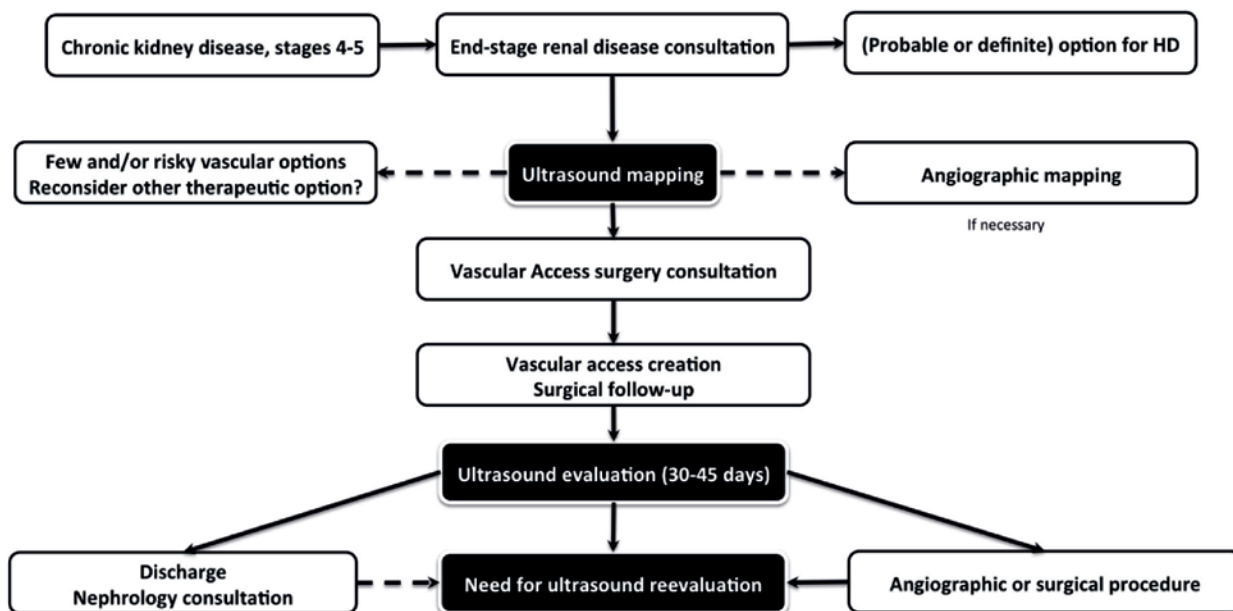
■ **A FINAL PRAGMATIC PROPOSAL**

Previous practice was to leave vascular access approach creation to surgeons and to refer a dysfunctional access to surgery or to angiographic evaluation.

At the present time, US assumes an intermediate/pivotal position in these processes.

Figure 1

Model for vascular mapping before arteriovenous access construction and follow-up



Given the theoretical advantages, the favorable clinical results and local experience, the following diagram for vascular access creation is suggested (Figure 1)

A different model should be adopted for prevalent arteriovenous access, i.e., for access that is being used. (Figure 2)

Portugal has a hemodialysis providing system based mainly in extra-hospital centers, and these are aggregated in different companies (and its respective vascular access centers). As such, a more complex model is required to uniformly assure optimal vascular access care.

There is an increasing availability of US machines; however nowadays there are still few in use. To address the needs of our population, two models are currently in use: 1) ultrasound is centralized in one site (vascular access center, for example), along with its difficult logistic and economical and patient burden and 2) rotation of the US machines in each peripheral unit, the last depending on the attributes of the local personnel (see previous chapter referring to risks and illusions in US evaluation).

Dealing with the current lack of US apparatus, the author would propose one paradox model where there is centralization of US evaluation but at a peripheral localization.

In sum, recognizably competent nephrologists in US evaluation would assume the evaluation of vascular access patients at their dialysis center, after referral. These evaluations would be performed jointly with nursing and local medical staff, to ultimately decide the plan (vigilance, puncture counselling, angiographic or surgical referral). Despite this, emergency evaluation should be still be assured by a vascular access center.

This allows for a less-error prone and uniform method of vascular access approach.

CONCLUSIONS

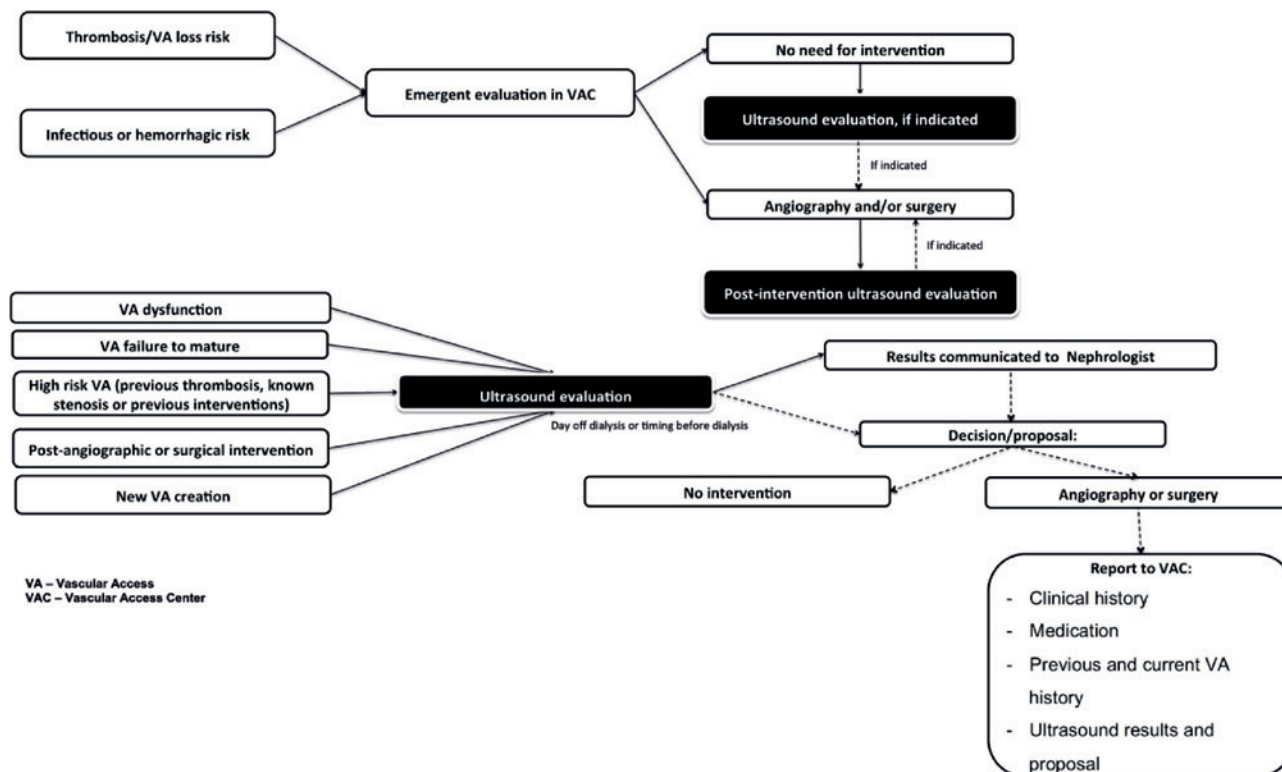
As with everything in life, innovation is at first mistrusted, then accepted and, eventually, becomes widely implemented.

This process is happening at an accelerated pace for US for vascular access care, as US seems to be one of the more breakthrough advances in this area. Along the way, many difficulties are encountered, and a mix of learning and effort is required to correctly implement this new tool.

Last, but not least, after its implementation, care should be taken to allow 1) maintenance of US-based decisions' quality and reliability,

Figure 2

Model for ultrasound evaluation of arteriovenous access in use



2) continuous training and practice of medical personal and 3) enhancement of vascular access programs (dialysis and pre-dialysis) using an easy-access and reliable ultrasound evaluation.

Disclosure of potential conflicts of interest: none declared

References

1. Ibeas J, Roca-Tey R. Guía Clínica española del acceso vascular para hemodiálisis. Nefrología. 2017; 37(1): 1-191.
2. Lok C, Huber T, Lee T, Shenoy S, Yezlin A, Abreo K, Allon M et al. KDOQI Clinical Practice Guideline for Vascular Access: 2019 Update. 2020; 75(4): S1-S164.
3. Gallieni M, Hollenbeck M, Inston N, Kumwenda M, Powell S, Tordoir J et al. Clinical practice guideline on peri and postoperative care of arteriovenous fistulas and grafts for haemodialysis in adults. Nephrol Dial Transplant. 2019; 34(2): 1-42.
4. Tonelli M, James M, Wiebe N, Jindal K, Hemmelgarn B. ultrasound monitoring to detect access stenosis in hemodialysis patients: a systematic review. Am J Kidney Dis. 2008; 51: 630-640.
5. Roca-Tey R, Rivas A, Samon R, Ibrik O, Viladoms J. Study of vascular access by color doppler ultrasonography. Comparison between delta-h and cdu methods in measuring VA blood flow rate. Nefrología. 2005; 25: 678-683.
6. Akoh J. Prosthetic arteriovenous grafts for hemodialysis. J Vasc Access. 2009; 10: 137-147.
7. Shroff R, Sterenborg R, Kuchta A, Arnold A, Thomas N, Stronach L, Padayachee S, Calder F. A dedicated vascular access clinic for children on haemodialysis: two years' experience. Pediatr Nephrol. 2016; 31(12): 2337-2344.
8. Huynh T, Garza B, Geer J, Broadbent K, Martinek W, Correa A, Swartz S, Srivaths S, Brewer E. The role of preoperative duplex ultrasound vessel mapping in determining primary failure of pediatric hemodialysis arteriovenous fistula. J Vasc Ultrasound. 2019. 43 (2): 63-68

Correspondence to:

Tiago Assis Pereira, MD
 Nephrology Department, Hospital Curry Cabral,
 Centro Hospitalar Lisboa Central
 Lisboa, Portugal
 E-mai: tiagoassispereira@gmail.com